

Foreign-body aspiration in an adult

Alia Qureshi, MD,* Abdollah Behzadi, MD, CM, MBA†

Foreign-body aspiration is often a serious medical condition demanding timely recognition and prompt action.¹ Delayed diagnosis and subsequent delayed treatment is associated with serious, and sometimes fatal complications.^{1,2} In adults, however, foreign-body aspiration can be tolerated and remain undetected for a long time. We describe a case in which there was delayed and seemingly innocuous presentation after aspiration of a large foreign body.

Case report

A 33-year-old man presented with a 1-week

history of intermittent minor hemoptysis. On questioning, he admitted to swallowing a foreign body 2 months earlier. His action was inspired by a television show on swallowing foreign bodies. He had tried to swallow a knife blade, after breaking the handle, which was then accidentally aspirated. He immediately suffered a severe choking sensation that eventually resolved. He continued to experience episodes of violent coughing but decided against obtaining medical advice. In fact, he proceeded to swallow a metallic spoon a few days later without any obvious clinical consequences. Repeated episodes of minor hemoptysis over the week preceding admission forced

him to seek medical attention. His medical history was significant for bipolar disorder. He denied having suicidal ideation, intention to harm himself or others, or a history of alcohol or drug abuse.

Except for showing slightly decreased air entry into his right lung, physical examination was noncontributory. Laboratory findings were within normal limits. Chest radiography revealed a 10-cm-long foreign object in the right main-stem bronchus (Fig. 1). Abdominal radiography demonstrated an 8-cm-long foreign object in the stomach (Fig. 2).

In the operating room, with the patient under general anesthesia, we attempted to

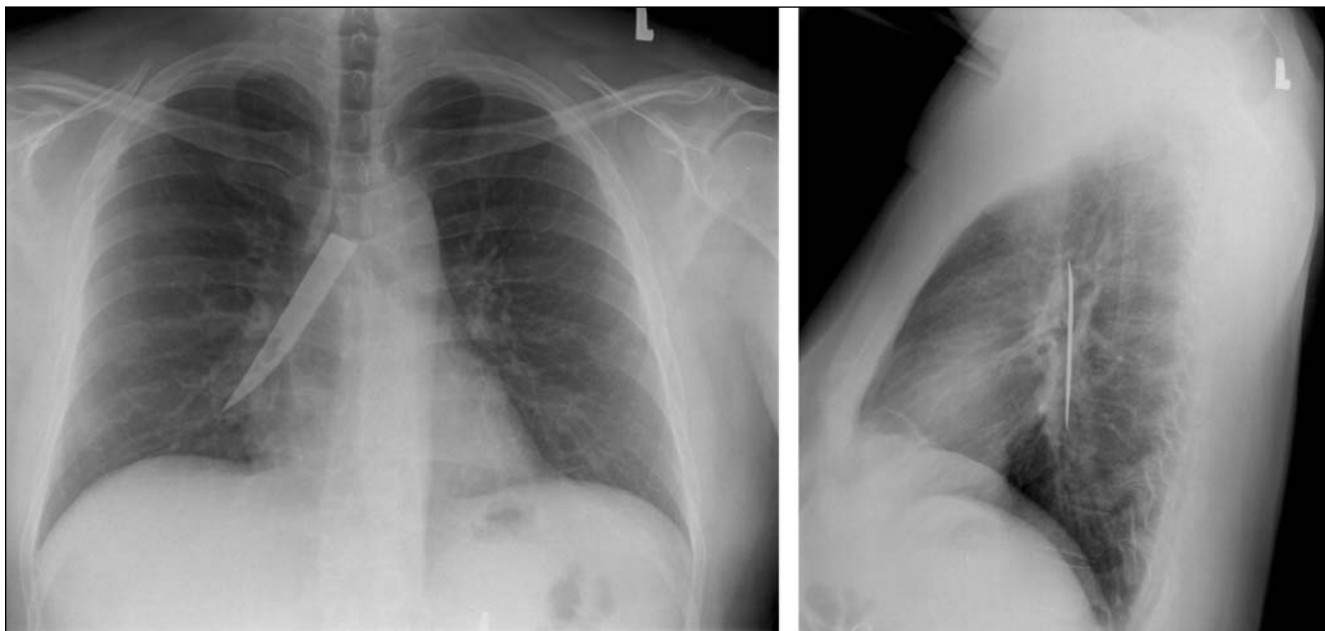


FIG. 1. Posteroanterior (left) and lateral (right) chest radiographs showing a metallic object (a steak-knife blade) in the right main-stem bronchus.

From the *Department of General Surgery, University of Toronto, Toronto, and the †Division of Thoracic Surgery, Scarborough Hospital, Scarborough, Ont.

Accepted for publication July 3, 2007

Correspondence to: Dr. A. Behzadi, Scarborough General Hospital Medical Mall, 3030 Lawrence Ave. E, Ste. 204, Scarborough ON M1P 2T7; fax 416 431-0836; abehzadi@tsh.to

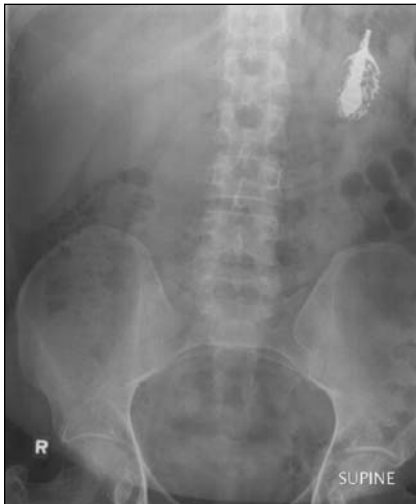

FIG. 2. Abdominal radiograph showing the retained foreign object in the stomach 2 months after ingestion.

extract the aspirated foreign body by flexible and rigid bronchoscopy. The endoscopic approach proved to be futile, and a right thoracotomy was performed. The 10-cm steak-knife blade was subsequently removed through a right tracheobronchotomy without complication. A week later, an attempt at endoscopic removal of the foreign body from the stomach was also unsuccessful. As this object had not passed beyond the stomach for many weeks and appeared to be partially embedded into the gastric wall, a gastrotomy was performed, and a partially digested metallic spoon was removed. After satisfactory psychiatric evaluation, the patient was discharged from the hospital about 4 weeks after admission. He continued to do well and had no evidence of airway stenosis on bron-

choscopic examination 12 months post-operatively.

Discussion

Unlike foreign-body aspiration in young children and in the elderly, this occurrence is uncommon in adults. In the adult population, such aspiration is most commonly secondary to unconscious accidental ingestion during general anesthesia, sedation, intoxication, seizures or neurologic disorders affecting the oropharynx.¹ The foreign bodies can be dietary or nondietary but are associated with similar sequelae.³ The symptoms of foreign-body aspiration range from coughing, wheezing and dyspnea to hemoptysis and choking.^{1,2} In most cases, the diagnosis is confirmed by chest radiography.⁴ Computed tomography of the chest maybe valuable in identifying small aspirated objects or when associated chest disease is suspected. Bronchoscopy is frequently both diagnostic and therapeutic.^{1,3} The availability of both rigid and flexible bronchoscopy should be emphasized since larger aspirates may not be retrievable with a flexible bronchoscope.³ Surgery constitutes the final, definitive option and is generally well tolerated, particularly when the lung parenchyma is spared.^{3,5}

What makes this case unusual is the rather delayed and innocuous presentation after aspiration of such a large foreign object. It emphasizes the fact that healthy adults may tolerate aspiration of foreign bodies for a long time without acute life-threatening consequences. As seen in this case, the chest radiograph shows the rather vertical position of the

right main-stem bronchus, facilitating more frequent aspiration than that of the left side. Bronchoscopic removal of large aspirated objects in general is an arduous task because most endoscopic instruments are unable to gain a firm and wide grasp of solid objects such as a knife blade, and the attempt is more locally traumatic than therapeutic. Hence, early involvement of a thoracic surgeon is of paramount importance in the management of large aspirated foreign bodies because expertise in both rigid and flexible bronchoscopy, as well as in airway surgery, is necessary.

Competing interests: None declared.

References

1. Baharloo F, Veyckemans F, Francis C, et al. Tracheobronchial foreign bodies: presentation and management in children and adults. *Chest* 1999;115:1357-62.
2. Willett LL, Barney J, Saylor G, et al. An unusual cause of chronic cough. Foreign body aspiration. *J Gen Intern Med* 2006; 21:C1-3.
3. Moura e Sá J, Oliveira A, Caiado A, et al. [Tracheobronchial foreign bodies in adults — experience of the Bronchology Unit of Centro Hospitalar de Vila Nova de Gaia]. *Rev Port Pneumol* 2006;12:31-43.
4. Pinto A, Scaglione M, Pinto F, et al. [Tracheobronchial aspiration of foreign bodies: current indications for emergency plain chest radiography]. *Radiol Med (Torino)* 2006;111:497-506. English, Italian.
5. Hasdiraz L, Bicer C, Bilgin M, et al. Turban pin aspiration: non-asphyxiating tracheobronchial foreign body in young Islamic women. *Thorac Cardiovasc Surg* 2006; 54:273-5.