

Unconsidered cause of bowel obstruction — gossypiboma

Deborshi Sharma, MS;* Arvind Pratap, MS;* Ashutosh Tandon, MB BS;* Ram Chandra Shukla, MD;†
Vijay K. Shukla, MCh*

Forgotten foreign bodies, such as cotton sponges, gauze or instruments, after any surgical procedure are considered a misadventure.¹ “Gossypiboma” denotes a mass of cotton that is accidentally retained in the body postoperatively. We describe a case in which a woman presented with features of intestinal obstruction about 10 months after open cholecystectomy.

Case report

A 30-year-old woman presented with a history of colicky pain in her upper abdomen along with constipation, vomiting and an episode of fresh bleeding per rectum about 1 month previously. She had undergone open cholecystectomy in a district hospital about 10 months earlier. On examination, a well-defined, nontender mass of 5 cm × 5 cm was palpable in her right hypochondrium. The lump was dull on percussion. No abnormality was detected in her supraclavicular lymph nodes or on digital rectal examination. Abdominal ultrasonography showed a hypoechoic bowel mass, colonoscopy revealed sessile polyps in the proximal transverse colon, and radiography after a barium meal showed a filling defect in her small bowel distally (Fig. 1).

At exploratory laparotomy, a mass of clumped loops of jejunum and transverse colon with internal fistulous connection was found. The bowel mesentery was

free of any enlarged lymph nodes. The transverse colon could be separated from the mass; however, the jejunal loops were densely adherent and hence were resected. When the bowel was opened along its antimesenteric border, a laparotomy sponge with the tail was found completely embedded in the bowel lumen (Fig. 2, Fig. 3). The tail had progressed more distally in the jejunum.

Discussion

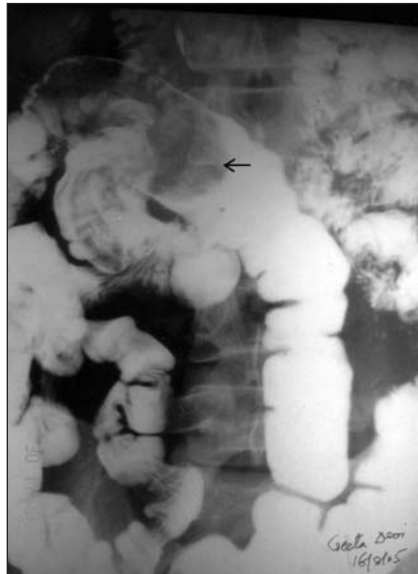

FIG. 1. Barium meal radiography with follow through demonstrates the intraluminal filling defect in the distal small bowel.

Missed or forgotten cotton sponge, gauze or, rarely, instruments after any surgery is a misadventure and is associated with several legal problems. The term “gossypiboma” denotes a mass of cotton retained in the body after any intervention.² Among the reported cases of foreign bodies retained postoperatively,

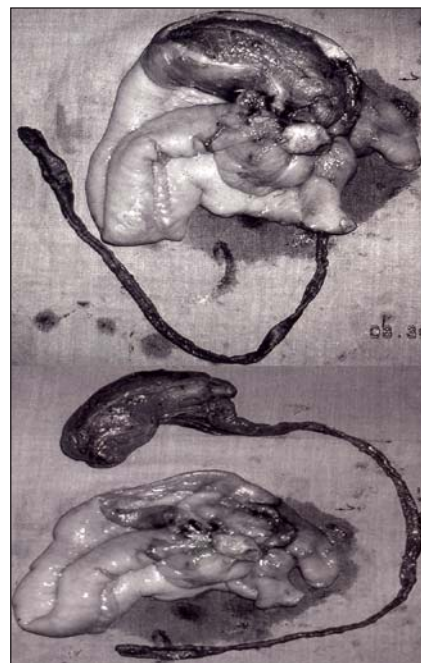


FIG. 2. Operative view after incision of the antimesenteric border and removal of the foreign body shows the clumped loops of small intestine with the sponge visible.

From the Departments of *Surgery and †Radiology, Institute of Medical Sciences, Banaras Hindu University, Varanasi, India

Accepted for publication Feb. 5, 2007

Correspondence to: Dr. Deborshi Sharma, Department of General Surgery, Institute of Medical Sciences, Banaras Hindu University, Varanasi-221005, India; fax 0091 542 2367568; deborshi_sh@yahoo.com

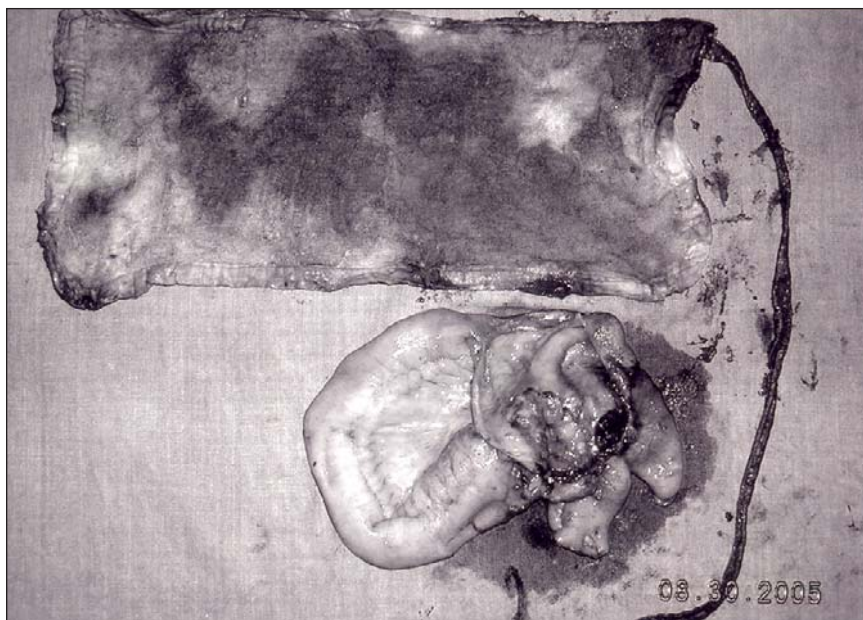


FIG. 3. View of the expanded gossypiboma with the tail.

the laparotomy sponge is the most common³ and is reported mostly after open cholecystectomy.⁴

The presentations associated with these cases vary from mild discomfort and pain and malabsorption symptoms to the severe pain of peritonitis or obstruction and can present many years after the initial surgical procedure.³⁻⁶ Gossypibomas are mostly detected incidentally by radiologic investigations such as CT or intraoperatively after the initial operations are long forgotten.² Physicians should be acutely aware of the condition to diagnose gossypiboma preoperatively.

A sponge can migrate into the intestinal lumen, urinary bladder or thorax.^{4,6} Transmural migration of a foreign body can occur in various intra-abdominal locations and is directly related to a seromuscular incision of the intestine, if made.¹ A hypothesis of foreign-body reaction, secondary infection, mass formation and remodelling has also been proposed.¹

Although surgery is the recommended mode of treatment, prevention is the best course and should be emphasized. In the operating room, there should always be a clear record of all for-

eign materials used during surgery, without exception. Textile materials used should be impregnated with radiopaque markers.² At the end of the procedure, the surgical site should be thoroughly checked for any retained foreign bodies.

Gossypiboma is an unwanted and preventable complication that should be considered as a rare differential diagnosis in all postlaparotomy patients presenting with mass lesions.

Competing interests: None declared.

References

1. Wattanasirichaigoon S. Transmural migration of a retained surgical sponge into the intestinal lumen: an experimental study. *J Med Assoc Thai* 1996;79:415-22.
2. Gencosmanoglu R, Inceoglu R. An unusual cause of small bowel obstruction: gossypiboma — case report. *BMC Surg* 2003;3:6.
3. Dhillon JS, Park A. Transmural migration of a retained laparotomy sponge. *Am Surg* 2002;68:603-5.
4. Dux M, Ganten M, Lubienski A, et al. Retained surgical sponge with migration into the duodenum and persistent duodenal fistula. *Eur Radiol* 2002;12(Suppl 3):S74-7.
5. Lone GN, Bhat AH, Tak MY, et al. Transdiaphragmatic migration of forgotten gauze sponge: an unreported entity of lung abscess. *Eur J Cardiothorac Surg* 2005;28:355-7.
6. Sinha SK, Gupta S, Behra A, et al. Retained surgical sponge: an unusual cause of malabsorption. *Trop Gastroenterol* 1999; 20:42-4.