

## Notes de cas

This raises the possibility of a previously unexplored contributory factor in the pathogenesis of traumatic VSD. In our case, the appearance of the tissue surrounding the defect displayed the gross appearance of a healed wound, and the initial echocardiogram did not demonstrate the VSD. This information, combined with a history of resolved childhood murmur, suggests that the traumatic VSD resulted from the result of a reopening healed congenital lesion in a weakened ventricular septum.

Clinical findings in traumatic VSD cases are relatively nonspecific, can be masked by other injuries and can often be delayed in presentation. The clinician should maintain a high level of suspicion for any new or un-

explained murmur or ECG findings.<sup>2</sup> This can be particularly challenging in patients with multiple injuries, with other injuries that require immediate attention. The transthoracic or transesophageal echo is the diagnostic test of choice. If promptly diagnosed and treated surgically, these patients enjoy excellent outcomes.

**Competing interests:** None declared.

### References

1. Cowgill LD, Campbell DN, Clarke DR, et al. Ventricular septal defect due to nonpenetrating chest trauma: use of the intra-aortic balloon pump. *J Trauma* 1987;27:1087-90.
2. Rollins MD, Koehler RP, Stevens MH, et al. Traumatic ventricular septal defect: case report and review of the English literature since 1970. *J Trauma* 2005;58:175-80.
3. Rutherford EJ, White KS, Maxwell JG, et al. Immediate isolated interventricular septal defect from nonpenetrating thoracic trauma. *Am Surg* 1993;59:353-5.
4. Olivier LR, Rossouw DS, de Villiers SJ, et al. Ventricular septal defect due to blunt chest trauma. A case report. *S Afr Med J* 1983;63:660-2.
5. Bright EF, Beck CS. Nonpenetrating wounds of the heart. *Am Heart J* 1935;10:293-321.
6. Williams GD, Hara M, Bulloch R. Traumatic ventricular septal defects. *Am J Cardiol* 1966;18:907-10.

# Aggressive angiomyxoma of the pelvis: a case report

Alex Mathieson, MD;\* Soorna Chandrakanth, MD;† George Yousef, MD;† Patricia Wadden, MD;† Eric Sala, MD;‡ Debrah Wirtzfeld, MD\*

First described by Steeper and Rosai in 1983,<sup>1</sup> aggressive angiomyxoma (AAM) is a mesenchymal tumour found mainly in the pelvis and perineum. There is a strong female predominance, with a female-to-male ratio of approximately 6:1. It is a slow-growing tumour with a high rate of local recurrence. Because of its rarity, it is often initially misdiagnosed, frequently as a gynecological malignancy.

### Case Report

A 47-year-old woman presented to a peripheral hospital with a mass in the left labia. Her medical history included a hysterectomy and left oophorectomy. The diagnosis of a Bartholin's cyst was made, and the patient was taken to the operating room (OR) for marsupialization. Further examination revealed that the mass was

not a Bartholin cyst. The operation was terminated and a CT scan was obtained. The CT showed a large pelvic mass (approximately 12 × 9 × 9 cm). A percutaneous biopsy was done, and histology showed a spindle cell tumour. MRI showed a mass 15 × 9 × 9 cm that enhanced well with gadolinium (see Fig. 1). MRI indicated that the mass did not involve the rectal wall or bladder. The mass did not appear to involve pelvic musculature but involvement of the proximal vaginal wall could not be ruled out. The patient was taken to the OR for resection. The mass was completely excised through a perineal incision that incorporated the previous biopsy site and Bartholin's surgery site. A posterior vaginectomy was done to get clear margins. There were no intraoperative complications, and blood loss was estimated at 200 mL. Final

pathological analysis revealed AAM. In 30 months of follow-up, there has been no clinical or radiographic (MRI) recurrence.

### Pathology

Microscopically, AAM shows stellate and spindle cells within a loose matrix with some collagen formation and vessels of varying size (Fig. 2). The stroma tends to be quite edematous, but in some fields, differentiation into smooth muscle cells is suggested. Mitotic activity is absent or infrequent. Fetsch and colleagues<sup>2</sup> reported that all 22 cases stained for desmin were positive; smooth muscle actin was found in 19 of 22 cases, and muscle-specific actin was present in 16 of 19 cases; vimentin was present in all 17 cases studied and CD34 (QBEND-10) in 8 of 16 cases. In contrast, S100 protein was ab-

From the Departments of \*Surgery, †Laboratory Medicine and ‡Diagnostic Imaging, Memorial University, St. John's, Nfld.

Accepted for publication Oct. 17, 2005

**Correspondence to:** Dr. Debrah Wirtzfeld, SM 439, Department of Surgery, St. Clare's Mercy Hospital, St. John's NL A1C 5B8; fax 709 777-5849; debrahw@nf.sympatico.ca

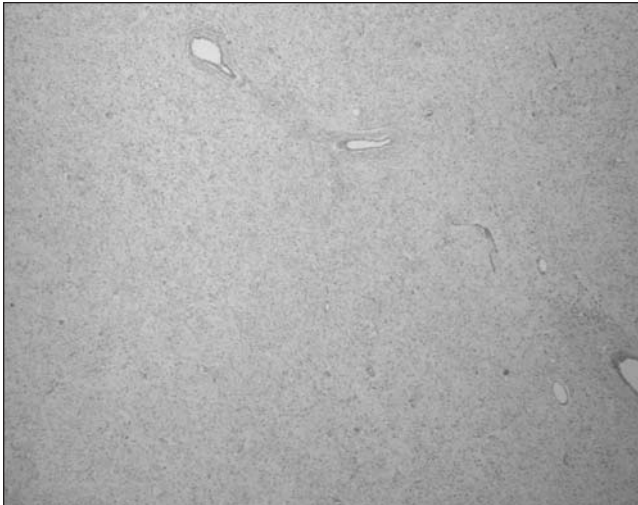


FIG. 1. MRI showing a mass  $15 \times 9 \times 9$  cm.

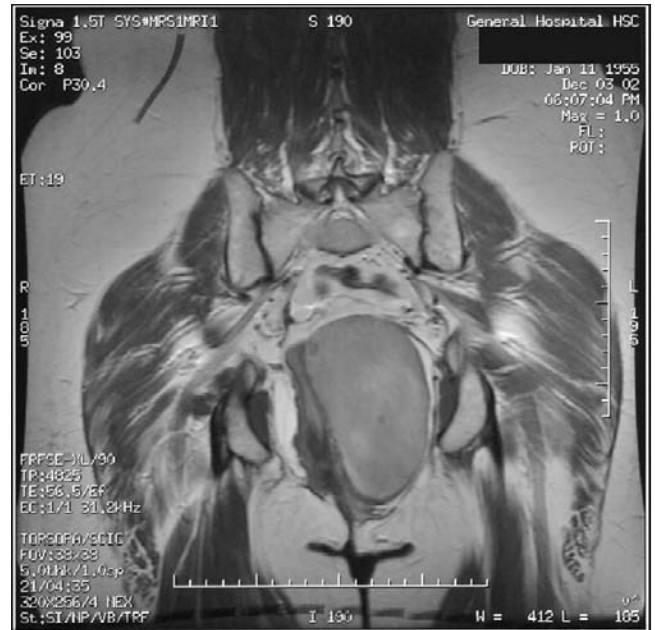

FIG. 2. Micrograph of aggressive angiomyxoma (low power).

sent in all 20 cases tested. Estrogen receptor was positive in 13 of 14 cases and progesterone receptor in 9 of 10 cases.

### Discussion

AAM is a rare tumour found mainly in the female pelvis. There are no large clinical trials to guide treatment, only case reports and small series, the largest of which identified 16 patients.

Surgical resection is the main treatment modality, but local recurrence rates are high. The reported recurrence rate varies from 35%–72%, even with clear surgical margins. Further resection for recurrence is possible in many cases. Resection of these tumours can be technically difficult, and the value of extensive surgical resection to obtain clear margins has been questioned.<sup>3</sup> Some cases that have had in-

complete resection have not developed clinical recurrence over several years of follow-up.<sup>2</sup> The morbidity of extensive resection must be balanced against the value of clear resection margins; reports of metastatic disease further complicate this problem.<sup>4,5</sup> The relation between resection margins and metastatic disease needs further study.

There are many unanswered questions about treatment and follow-up strategies for this rare disease. Because this tumour is slow growing and is often symptomatic only when the tumour is large, radiographic follow-up is best. Resection with clear margins, when feasible, is the best treatment. The patient we report has thus far done well with no clinical or radiographic recurrence.

**Competing interests:** None declared.

### References

1. Steeper TA, Rosai J. Aggressive angiomyxoma of the female pelvis and perineum: report of nine cases of a distinctive type of gynecologic and soft-tissue neoplasm. *Am J Surg Pathol* 1983;7:463-75.
2. Fetsch JF, Laskin WB, Lefkowitz M, et al. Aggressive angiomyxoma: a clinicopathologic study of 29 female patients. *Cancer* 1996;78:79-90.
3. Chan IM, Hon E, Ngai SW, et al. Aggressive angiomyxoma in females: is radical resection the only option? *Acta Obstet Gynecol Scand* 2000;79:216-20.
4. Siassi RM, Papadopoulos T, Matzel KE. Metastasizing aggressive angiomyxoma. *N Engl J Med* 1999;341:1772.
5. Blandamura S, Cruz J, Vergara LF, et al. Aggressive angiomyxoma: a second case of metastasis with patient's death. *Hum Pathol* 2003;34:1072-4.