

Surgical images: soft tissue

Calcinosis cutis

A 71-year-old woman with new onset end-stage renal failure of unknown origin presented with symptoms of uremia (nausea, vomiting, purities, dyspnea, fatigue). Physical examination revealed an area of dry gangrene on the left leg. Laboratory investigations demonstrated a urea of 47.6 mmol/L, creatinine level of 884 μ mol/L, hemoglobin of 60 g/L, calcium of 3.5 mmol/L, a phosphate level of 2.15 mmol/L, a calcium phosphorus product of 93 ($[Ca] \times [PO_4]$ in conventional units) and a parathyroid hormone of 1138 pg/mL. The patient was placed on hemodialysis. The gangrenous lesion was presumed to be related to the patient's venous insufficiency.

Over the next 2 months, there was progression of the dry gangrene involving the anterior and posterior aspect of both upper legs, the posterior and lateral

aspect of the lower legs, the lower back and the buttocks (Fig. 1). A thromboembolic etiology was considered, and the patient was placed on heparin. A skin biopsy of the lesion showed no evidence of emboli, and an echocardiogram failed to reveal a source.

The patient was referred to our centre, where a bilateral leg x-ray revealed calcification of the small arteries of both legs (Fig. 2). A second skin biopsy established the diagnosis of calcinosis cutis (Fig. 3) due to hyperparathyroidism. An urgent parathyroidectomy was performed. At parathyroidectomy, a large, fixed, right superior parathyroid gland and a normal looking right inferior gland were visualized and removed.

On gross examination, the right superior specimen weighed 3.96 g, with the gland measuring from $2.7 \times 2.1 \times 1.5$ cm

in size (Fig. 4). The inferior parathyroid gland measured $1 \times 0.65 \times 0.4$ cm and weighed 0.073 g. Microscopic examination of the right superior gland demonstrated hypercellularity and calcification. Gross and microscopic findings were consistent with parathyroid adenoma.

The patient's condition deteriorated postoperatively; she developed pneumo-

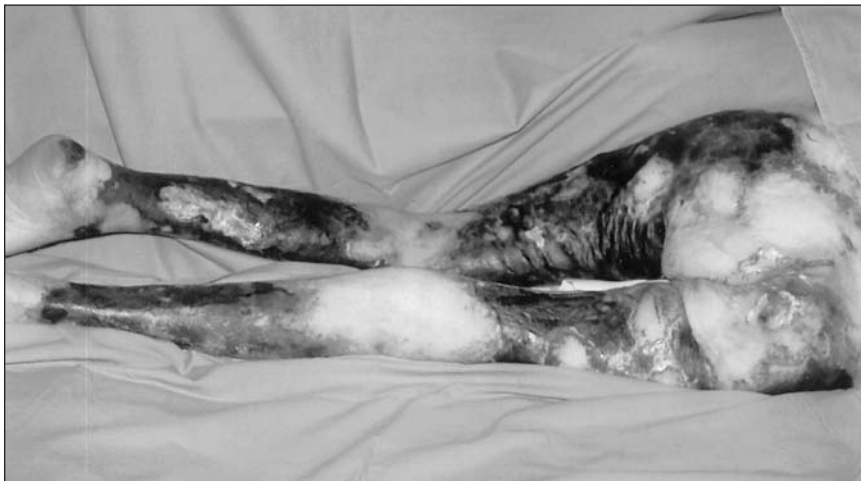

FIG. 1. Photograph taken at operating room showing the extent of the necrotic skin lesions.

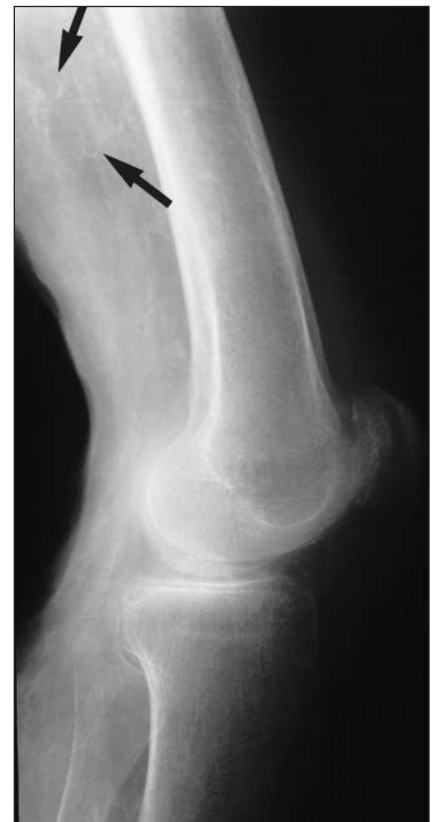

FIG. 2. Radiograph of the left leg. The arrow shows calcified small blood vessels.

Submitted by Luc A. Dubois, MD,* Daryl K. Gray, MD,* Edward J. Tweedie, MD,† from the Divisions of *General Surgery and †Pathology, University of Western Ontario, London, Ont.

Correspondence to: Dr. Daryl K. Gray, London Health Sciences Centre – Victoria Campus, E2-217B, 800 Commissioners Rd, London Ontario N6A 5W9; 519 667-6546; daryl.gray@lhsc.on.ca

Submissions to the Surgical Images, soft-tissue section, should be sent to the section editors: Dr. David P. Girvan, Victoria Hospital Corporation, PO Box 5375, Station B, London ON N6A 5A5 or Dr. Nis Schmidt, Department of Surgery, St. Paul's Hospital, 1081 Burrard St., Vancouver BC V6Z 1Y6.

nia and bilateral pleural effusions and became hypotensive. Due to the extent of the necrotic tissue in her legs, the need for surgical débridement and amputation, and her concomitant medical prob-

lems, the family decided to withdraw care. The patient died of overwhelming sepsis.

Calcinosis cutis (also known as calciphylaxis), the progressive deposition of cal-

cium in the skin and small blood vessels with associated thrombosis and necrosis, is a rare and life-threatening illness. It most commonly results from hyperparathyroidism secondary to renal failure and most commonly occurs in women.¹ Calcinosis cutis typically presents with ulcerating painful purplish lesions in the extremities and trunk. These lesions often progress to necrosis and act as a portal for infectious agents leading to wound sepsis and death.² The etiology of this disease remains unclear, however, and elevated calcium phosphorous product ($[Ca] \times [PO_3] > 70$ in conventional units) is thought to act as a sensitizer, promoting calcification. Elevated levels of parathyroid hormone have also been implicated as a sensitizer.¹ Treatment is difficult, with such medical therapies as phosphate binders and steroids having little effect.³ The best current therapy is systemic antibiotic drugs, débridement of necrotic tissue and semi-urgent parathyroidectomy.¹⁻⁴ Early parathyroidectomy has been shown to significantly reduce mortality in a study of 104 patients with calcinosis cutis and renal failure.⁴ Despite these results, the literature would agree that the current therapy remains unsatisfactory.¹⁻³ Calcinosis cutis can be difficult to diagnose on pathology; thus, if the clinical suspicion of calcinosis remains high after a negative skin biopsy, it is wise to repeat it.

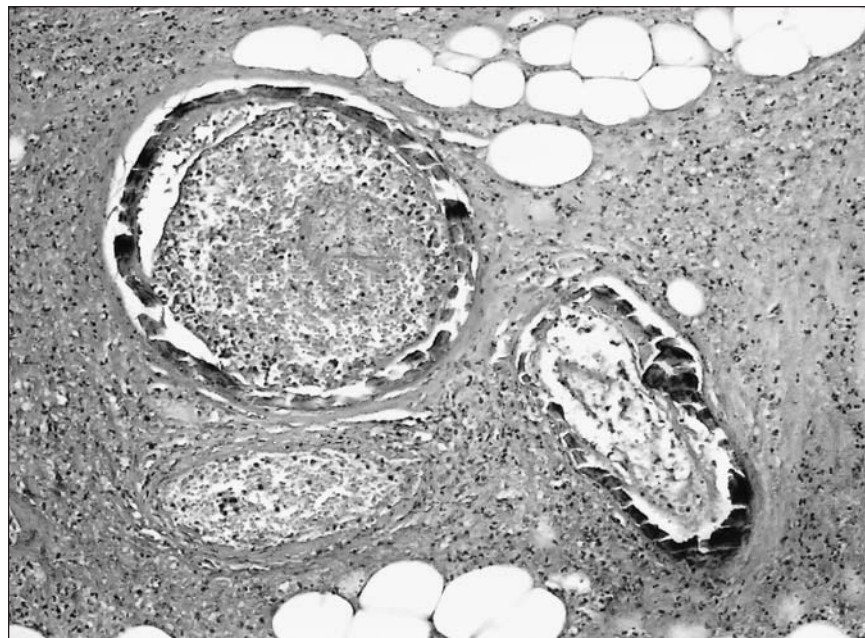


FIG. 3. 100 × (hematoxylin and eosin) micrograph of cutaneous arteries showing extensive mural calcification, luminal thrombosis and necrosis of surrounding tissue.

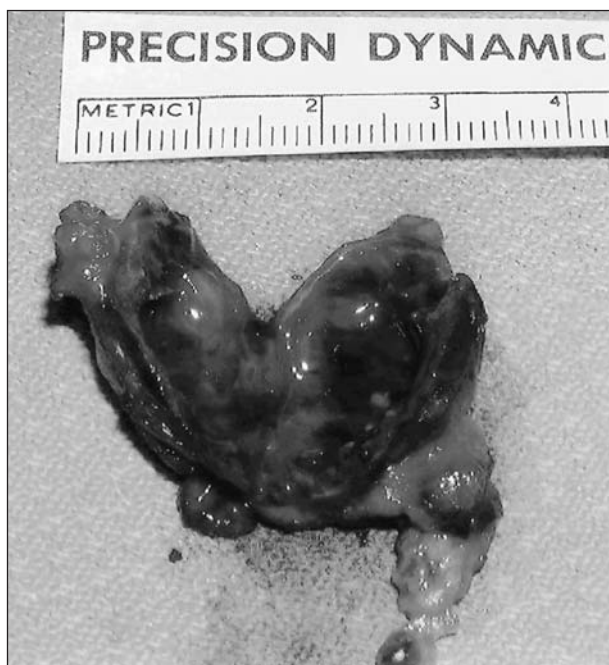

FIG. 4. Right superior parathyroid adenoma (3.96 g).

Competing interests: None declared.

References

1. Ledbetter LS, Khoshnevis MR, Hsu S. Calciphylaxis. *Cutis* 2000;66:49-51.
2. Gilson RT. Calciphylaxis: case report and treatment review. *Cutis* 1999;63:149-53.
3. Shriner DL, Leevy CB, Schwartz RA, et al. Calcinosis cutis associated with secondary hyperparathyroidism due to renal failure. *Int J Dermatol* 1996;35:885-7.
4. Hafner J, Keusch G, Wahl C, et al. Uremic small-artery disease with medical calcification and intimal hyperplasia (so-called calciphylaxis): a complication of chronic renal failure and benefit from parathyroidectomy. *J Am Acad Dermatol* 1995;33:954-62.