

Soft-tissue images. Segmental colonic ischemia mimicking appendicitis

A 53-year-old woman was admitted with a 1-day history of abdominal pain on the right side. Results of abdominal computed tomography done at another hospital the evening before were normal. The patient also had anorexia, nausea, vomiting and diarrhea, and she smoked. Three months earlier she had had a myocardial infarction treated by percutaneous transluminal coronary angioplasty and insertion of a stent. One month later echocardiography showed only minimal abnormality of ventricular wall motion and no mural thrombus. She was taking lovastatin, metoprolol, lisinopril, levothyroxine, conjugated estrogens and acetylsalicylic acid.

On physical examination she was found to have a low-grade fever and local rebound tenderness in the right portion of the midabdomen. A stool sample was negative for occult blood. The leukocyte count was $16.3 \times 10^9/L$.

Exploratory laparotomy for suspected appendicitis revealed segmen-

tal ischemia of the ascending colon (Fig. 1). A right colectomy was

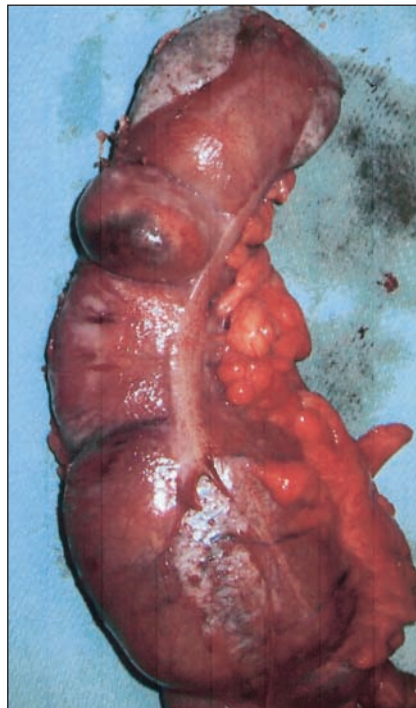


FIG. 1. Operative view of the resected segment of colon shows segmental ischemia.

done. Her recovery was uncomplicated. Histologic examination of the biopsy specimen showed focal full-thickness necrosis and normal mesenteric vessels.

Segmental ischemia of the right side of the colon is a rare cause of abdominal pain.¹ Emboli, vasculitis or systemic hypotension may cause this condition, and treatment usually should include resection of the abnormal segment of the colon. For older patients with a normal appendix and right-sided abdominal pain, the differential diagnosis should include segmental ischemia of the right side of the colon.

Acknowledgement: We thank the Kaiser Foundation Hospitals Medical Editing Department for assistance.

Reference

1. Schuler JG, Hudlin MM. Cecal necrosis: infrequent variant of ischemic colitis. Report of five cases. *Dis Colon Rectum* 2000;43:708-12.

Submitted by James H. McClenathan, MD, and Ninad Dabadghav, MD, Department of Surgery, Kaiser Permanente Medical Center, Santa Clara, Calif.

Submissions to *Surgical Images*, soft-tissue section, should be sent to the section editors: Dr. David P. Girvan, Victoria Hospital Corporation, PO Box 5375, Station B, London ON N6A 5A5 or Dr. Nis Schmidt, Department of Surgery, St. Paul's Hospital, 1081 Burrard St., Vancouver BC V6Z 1Y6.

Correspondence to: Dr. James H. McClenathan, Department of Surgery, Kaiser Permanente Medical Center, 900 Kiely Blvd., Santa Clara CA 95051-5386, USA; fax 408 236-4868; james.mcclenathan@kp.org