

Soft-tissue images. Pseudomyxoma peritonei and villous adenoma of the appendix

A 54-year-old woman was referred for investigation of a mass in the right lower quadrant found incidentally on transvaginal ultrasonography. Computed tomography (Fig. 1) showed a complex cystic mass arising in the right retrocecal area, measuring $8 \times 5 \times 2$ cm in dimension. Her medical history included an uncomplicated laparoscopic cholecystectomy done 2 years earlier.

At laparotomy, a large retrocecal cystic mass was encountered that arose from a grossly distended, perforated appendix. A large amount of mucin had extravasated from the perforated appendix into the retroperitoneal area (Fig. 2). A right hemicolectomy was done, removing all mucin in the retroperitoneum. The area was irrigated thoroughly.

Pathological examination of the excised specimen revealed a mucinous cyst with a necrotic lining containing acellular mucin. A villous adenoma, 2×2 cm in dimension, was found arising in the appendix. There was no suggestion of malignancy (Fig. 3), and no malignant cells were found in any of the 18 lymph nodes identified.

Pseudomyxoma peritonei is a rare complication of intra-abdominal

neoplasia. It is characterized by the slow accumulation of gelatinous material in the peritoneal cavity as a result of rupture of an adenoma, adenocarcinoma or a mucinous cyst of the ovary or appendix. If the antecedent lesion is malignant, rupture will result in seeding of malignant cells into the peritoneum.¹

Mucoceles of the appendix have

been defined as an abnormal accumulation of mucus, distending the appendiceal lumen, regardless of the underlying cause.² Recurrent inflammation, fecalith, carcinoid, carcinoma, villous adenoma and endometriosis are causes of obstruction of the appendiceal lumen that may potentiate mucoceles. There are several different classifications of muco-

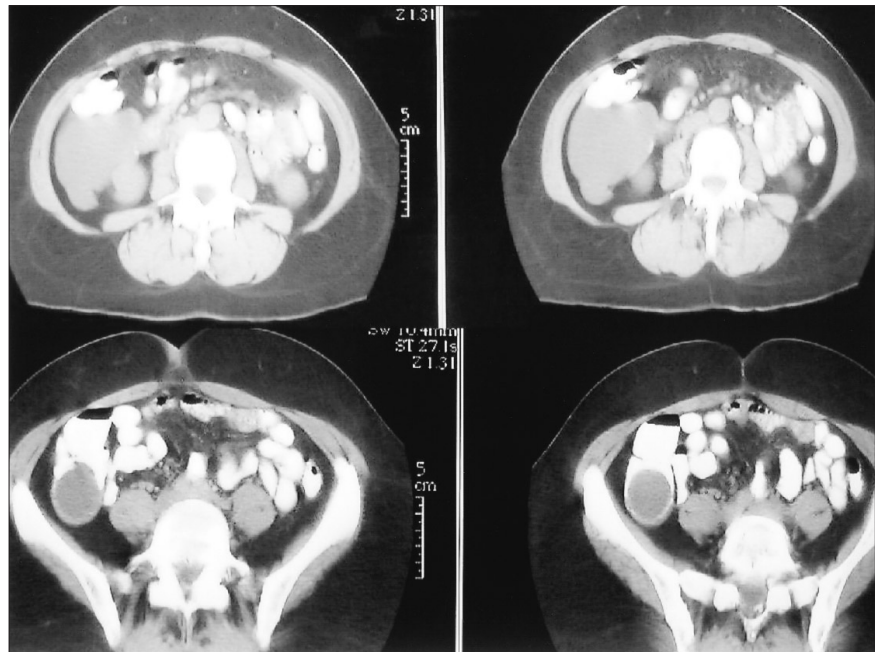

FIG. 1. Computed tomography scans of the abdomen demonstrate a large complex mass in the right retrocecal region.

Section Editors: David P. Girvan, MD, and Nis Schmidt, MD

Submitted by Shiva Jayaraman, BSc,* Madeleine Moussa, MD,† and Daryl K. Gray, MD,‡ *Medical student, University of Western Ontario, †Department of Pathology, and ‡Division of General Surgery, Faculty of Medicine and Dentistry, University of Western Ontario, London, Ont.

Submissions to *Surgical Images*, soft-tissue section, should be sent to Dr. David P. Girvan, Victoria Hospital Corporation, PO Box 5375, Station B, London ON N6A 5A5 or to Dr. Nis Schmidt, Department of Surgery, St. Paul's Hospital, 1081 Burrard St., Vancouver BC V6Z 1Y6.

Correspondence to: Dr. Daryl K. Gray, Division of General Surgery, London Health Sciences Centre, 375 South St., London ON N6A 4G5; fax 519 667-6546, daryl.gray@lhsc.on.ca

© 2002 Canadian Medical Association

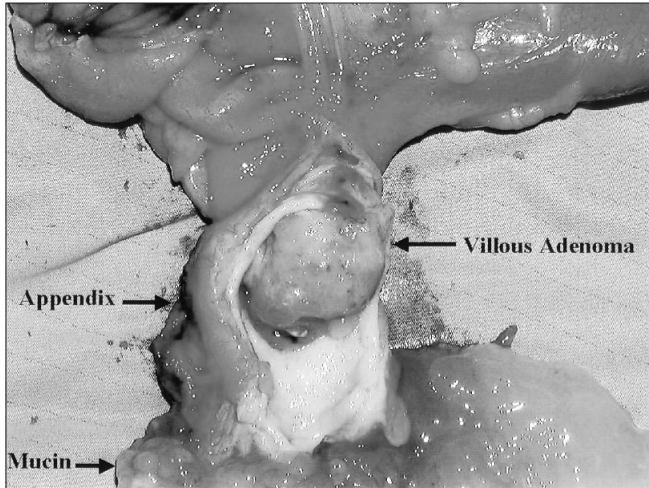


FIG. 2. Excised specimen, showing the appendix, a villous adenoma within it and a large amount of mucin.

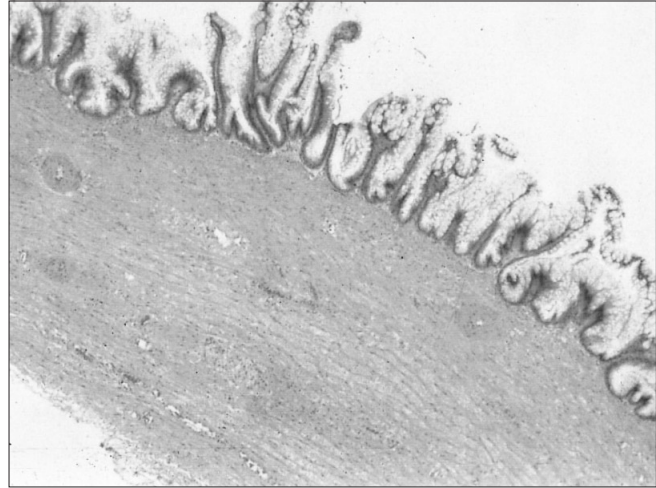


FIG. 3. Microscopic view, showing villous adenoma of the appendix. Note that there is no invasion of cells into the bowel wall (hematoxylin-eosin, original magnification $\times 10$).

celes; however, the most important distinction is that between benign and malignant lesions. Some suggest that the mere presence of pseudomyxoma peritonei implies malignancy in the form of low-grade cystadenocarcinoma.³ Others believe that in the absence of atypical cells in the mucin, and with lymph nodes negative for malignant cells, a malignant lesion may be excluded.⁴ Most of the literature supports the latter assertion and suggests that mucinous adenocarcinoma may be excluded if the mucocele's lining shows no atypia.⁴ However, owing to the presence of intracytoplasmic canaliculi in pseudomyxoma peritonei, Elesha and associates³ believed that this clinical entity represents a malignant lesion even in the presence of normal epithelial cells.

Mucoceles arising in the appendix affect men and women equally. Some patients have intense abdominal pain and distension; others have nausea and vomiting. As many as 23% to 50% of cysts are asymptomatic and are found incidentally on abdominal or pelvic imaging. A mass is palpable in 50% of cases. Ultrasonography shows a typical cystic structure with a thin wall in many cases. On computed tomography, mucoceles have low attenuation, often with calcifications in their walls. The size and shape of the lesions can be extremely heterogeneous. Low-attenuation ascites is often indicative of pseudomyxoma peritonei.⁴

Despite the controversy over the malignant potential of mucoceles with pseudomyxoma peritonei, the literature consistently supports com-

plete excision of the mass. In addition, removal of all free mucin and thorough irrigation are advocated.

References

1. Lee YT, Lau JY, Chan KF, Chung SC, Sung JJ. Endosonographic features of pseudomyxoma peritonei. *Gastrointest Endosc* 2000;51(1):85-8.
2. Dachman AH, Lichtenstein JE, Friedman AC. Mucocele of the appendix and pseudomyxoma peritonei. *AJR Am J Roentgenol* 1985;144(5):923-9.
3. Elesha SO, Medline A, Taylor BR. Mucocele of the appendix: pseudomyxoma peritonei and intracytoplasmic canaliculus-like structures. *Hum Pathol* 1981;12(3):280-3.
4. Rammou-Kinia R, Sirmakechian-Karra T. Pseudomyxoma peritonei and malignant mucocele of the appendix. A case report. *Acta Cytol* 1986;30(2):169-72.