

Soft-tissue images. Trocar-site hernia after laparoscopic procedures

A 54-year-old woman was admitted for elective laparoscopic repair of a recurrent ventral hernia. She had undergone open cholecystectomy and gastric bypass for obesity in 1990. Three years later a ventral hernia developed. This was repaired with mesh. When the hernia recurred, she was referred for laparoscopic repair.

Once the hernia was reduced, polypropylene mesh was placed intraperitoneally and extracorporeally sutured with nonabsorbable suture material to the surrounding fascia. Fascia was reapproximated at the trocar sites. The patient was discharged 2 days later.

Three days after discharge, the patient was readmitted, complaining of nausea, cramping abdominal pain and constipation. Clinical examination and radiography were consistent with a partial small-bowel obstruction (SBO). She was treated conservatively with nasogastric suction and intravenous administration of fluids. Over the next 72 hours her symptoms partially improved but did not resolve. Computed tomography of the abdomen and small-bowel follow-through (SBFT) contrast study were

done. The SBFT showed a fixed defect, consistent with a Richter's hernia of the mid-small bowel in the left upper quadrant (Fig. 1). Computed tomography revealed a soft-tissue density protruding outside the fascia in the left upper quadrant (Fig. 2), confirming the diagnosis.

Laparoscopy demonstrated the Richter's hernia through a previous trocar site (Fig. 3). The hernia was explored locally and viable small bowel reduced (Fig. 4). The fascial defect was repaired primarily. The patient made a smooth recovery and was discharged 4 days postoperatively.

This case illustrates a rare complication of laparoscopic surgery as well as key points in managing these patients. Herniation through a trocar site occurs in 0.2% to 1.0% of laparoscopic surgical procedures¹ and can result in significant morbidity. All trocar sites larger than 5 mm diameter should have the fascia reapproximated to minimize hernia formation. This may be more difficult in obese patients because visualization of fascia may be suboptimal. Accurate approximation should be accomplished by endoscopic placement of fascial sutures under direct vision. Patients

who undergo laparoscopic surgery usually have a short uncomplicated postoperative course. Any deviation from this requires aggressive investigation and treatment. Recently, Velasco and colleagues² stated that SBO within 2 weeks of a laparoscopic pro-

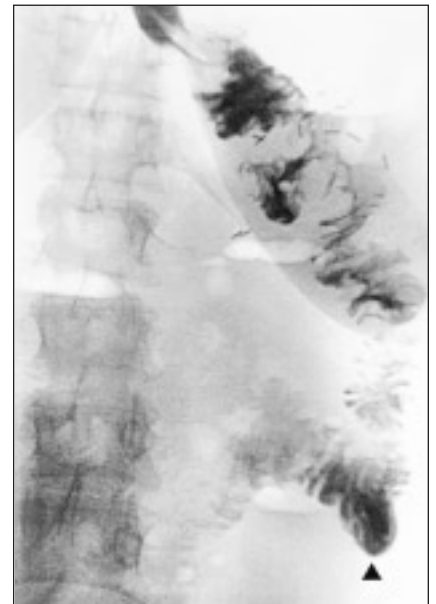


FIG. 1. Small-bowel follow-through contrast study shows a fixed small-bowel defect in the left upper quadrant. Contrast medium is seen passing distally (arrowhead).

Section Editors: David P. Girvan, MD, and Nis Schmidt, MD

Submitted by Margherita O. Cadeddu, MD, Christopher M. Schlachta, MD, CM, Joseph Mamazza, MD, CM, Pieter A. Seshadri, MD, and Eric C. Poulin, MD, MSc, University of Toronto Centre for Minimally Invasive Surgery, St. Michael's Hospital, Toronto, Ont.

Submissions to *Surgical Images*, soft-tissue section, should be sent to Dr. David P. Girvan, Victoria Hospital Corporation, PO Box 5375, Station B, London ON N6A 5A5 or to Dr. Nis Schmidt, Department of Surgery, St. Paul's Hospital, 1081 Burrard St., Vancouver BC V6Z 1Y6.

Correspondence to: Dr. Eric C. Poulin, St. Michael's Hospital, Wellesley Central Site, 218 Jones Bldg., 160 Wellesley St. E, Toronto ON M4Y 1J3; pouline@smh.toronto.ca

© 2002 Canadian Medical Association

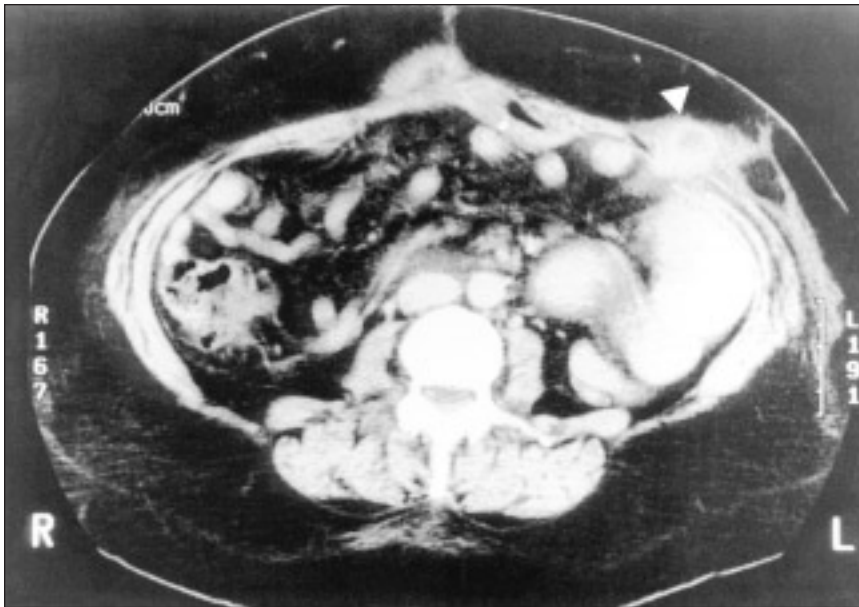


FIG. 2. Computed tomography of the abdomen demonstrates a soft-tissue density (arrowhead), containing oral contrast medium protruding outside the fascia in the left upper quadrant. Proximal small-bowel dilatation is also seen.

cedure should be considered due to trocar-site herniation until proven otherwise. In these circumstances, computed tomography is the diagnostic tool of choice. This presentation of SBO, unlike the majority of obstructions encountered after laparotomy, does not improve with conservative management and requires early reduction of hernia contents and repair of the trocar-site hernia.

References

1. Petrakis I, Sciacca V, Chalkiadakis G, Vasilakis SI, Xynos E. A simple technique for trocar site closure after laparoscopic surgery. *Surg Endosc* 1999;13:1249-51.
2. Velasco JM, Vallina VL, Bonomo SR, Hicken TJ. Postlaparoscopic small bowel obstruction. *Surg Endosc* 1998;12:1043-5.

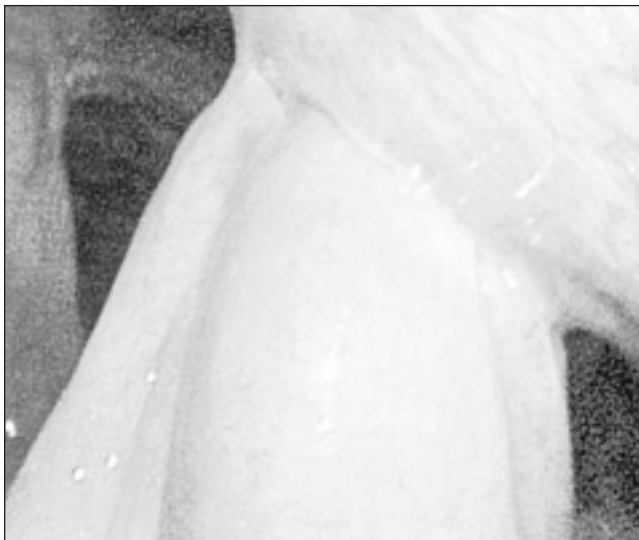

FIG. 3. A dilated loop of small bowel is herniating through the fascia of the anterior abdominal wall.

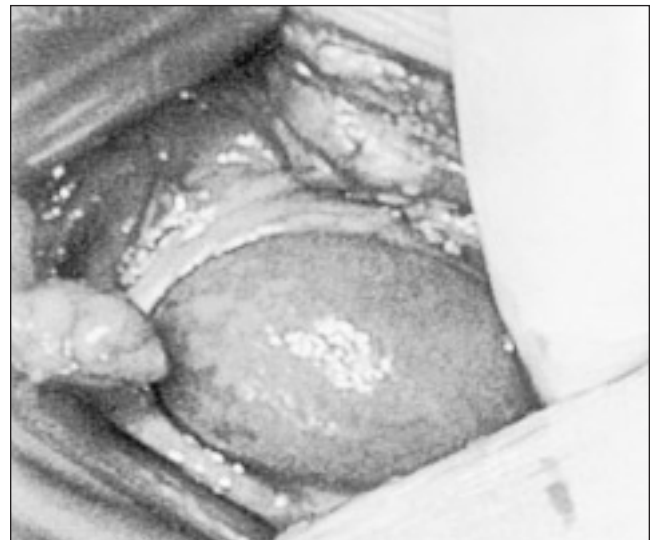


FIG. 4. Extension of the trocar site shows a Richter's hernia with viable small bowel.