

# Toe-to-finger transfer for post-traumatic reconstruction of the fingerless hand

J. Scott Williamson, MD;\* Ralph T. Manktelow, MD; Louise Kelly, BScOT, A. Marcuzzi, BScPT, Raman C. Mahabir, BSc, MD†

**Objective:** To assess the utility of toe-to-finger transfers (TFTs) for post-traumatic reconstruction of the fingerless hand. **Design:** A case series. **Setting:** A regional trauma centre. **Patients:** Eight men, mean age was 36 years (range from 25–59 yr), who had lost all the fingers from a hand due to a crush-degloving injury (6 patients), frostbite (1 patient) or a burn injury (1 patient). **Intervention:** TFT. Twelve TFTs were done and the mean time from injury to reconstruction was 17.2 months. **Main outcome measures:** Objective (range of motion, moving 2-point discrimination, grip strength, key pinch, Jebsen–Taylor hand assessment, return to work) and subjective (activities of daily living and a questionnaire) measures. **Results:** Eleven of the 12 transfers survived. Six of the 7 in whom the transfer was successful were available for follow-up (mean 45 mo). Range of motion was 10° at the distal interphalangeal joint, 18° at the proximal interphalangeal joint and 59° at the metacarpophalangeal joint. Sensation was protective in all. Grip strength and key pinch were 26.1% and 70.2% of the contralateral hand respectively. Jebsen–Taylor assessment indicated that basic activities were possible but slowed. All 6 patients returned to work and could perform 92.6% of the activities of daily living unassisted. Hand and foot symptoms were mild. Two-thirds were appearance conscious, 5 of the 6 went on to altered vocations and all reported overall satisfaction as high. **Conclusion:** This study supports TFT for reconstruction of the fingerless hand in that, although transferred toe function may be poorer than a normal finger, the hand is restored to a useful, sensate and versatile functional unit, such that global hand and patient function, as well as patient satisfaction, are very good.

**Objectif :** Évaluer l'utilité des transferts d'orteil au rayon du doigt (TFT) dans la reconstruction post-traumatique d'une main amputée de ses doigts. **Conception :** Série de cas. **Contexte :** Centre régional de traumatologie. **Patients :** Huit hommes âgés en moyenne de 36 ans (intervalle de 25 à 59 ans) qui ont perdu tous les doigts d'une main suite à une lésion par écrasement avec dégantage (6 patients), à une gelure (1 patient) ou à une brûlure (1 patient). **Intervention :** TFT. On a pratiqué 12 interventions de TFT et il s'est écoulé en moyenne 17,2 mois entre le traumatisme et la chirurgie reconstructive. **Principales mesures de résultats :** Des mesures objectives (amplitude du mouvement, discrimination spatiale dynamique, force de préhension, force de la pince sub-termino-latérale, évaluation de la fonction de la main de Jebsen–Taylor, retour au travail) et subjectives (activités de la vie quotidienne et réponses à un questionnaire). **Résultats :** Onze des douze transferts ont survécu. Six des sept patients chez qui le transfert a réussi se sont prêtés au suivi (45 mois en moyenne). L'amplitude du mouvement s'établissait à 10° à l'articulation interphalangienne distale, à 18° à l'articulation interphalangienne proximale et à 59° à l'articulation métacarpophalangienne. Les sensations de protection étaient présentes dans tous les cas. Les forces de préhension et de la pince sub-termino-latérale représentaient

---

From the Division of Plastic Surgery, Department of Surgery, University of Toronto, and the University of Toronto Hand Program, Toronto, Ont.

\*Clinical Instructor, Division of Plastic Surgery, Department of Surgery, University of British Columbia, Vancouver, BC, and Kelowna General Hospital, Kelowna, BC

†Clinical Research Fellow, University of British Columbia and the Okanagan Plastic Surgery Centre, Kelowna, BC

Presented at the annual meetings of the British Columbia Section of Plastic Surgery, Vancouver, BC, May 18 and 19, 1995, and the Canadian Society of Plastic Surgeons, May 22 to 25, 1996, Halifax, NS.

Accepted for publication Feb. 26, 2001.

**Correspondence to:** Dr. J. Scott Williamson, 601–1726 Dolphin Ave., Kelowna BC V1Y 9R9; fax 250 868-9031

© 2001 Canadian Medical Association

respectivement 26,1 % et 70,2 % de celles de la main controlatérale. L'évaluation de Jebsen-Taylor indiquait que les activités essentielles étaient faisables mais au ralenti. Les six patients sont retournés au travail et pouvaient pratiquer sans aide 92,6 % des activités de la vie quotidienne. Les symptômes à la main et au pied étaient légers. Les deux tiers des six participants étaient gênés par l'aspect de leur main, cinq d'entre eux ont entrepris des activités professionnelles adaptées, et ils ont tous signalé que leur niveau global de satisfaction était élevé. **Conclusion** : Cette étude appuie le recours à l'intervention de TFT pour la reconstruction d'une main amputée des doigts, du fait que même si la fonction de l'orteil transféré peut s'avérer inférieure à la fonction normale d'un doigt, la main ainsi rétablie est un instrument fonctionnel utile, polyvalent et pourvu de sensations, de sorte que la fonction globale de la main et du sujet ainsi que la satisfaction du patient sont très bonnes.

Severe mutilating hand injuries with multiple unsalvageable digit amputations often result from major crushing-degloving injuries and leave a hand with significant functional compromise when 2 or more digits are missing.<sup>1-3</sup> This is particularly so when there is loss of the radial digit (thumb) or 3 to 4 ulnar (fingers) opposable units, or both, limiting the basic hand functions of pinch, grasp and hook.

Reconstruction of the thumb has received greater attention than the fingers because it is critical to hand function and is more commonly absent. Functional thumb restorations with prostheses and a variety of non-microsurgical techniques have been described and may be appropriate for limited defects.<sup>4-6</sup> However, for greater deficits these options are less appropriate, and reconstruction with various types of free toe transfers has become so well established that it is widely considered the superior choice in many instances.<sup>3,7-12</sup>

When only a functional thumb is present, the hand is likewise incapacitated without the opposable fingers required for the thumb to work against in affording the hand its prehensile abilities. A similar array of treatment options exists for finger reconstruction and includes prosthetic, osteoplastic and toe-transfer techniques.

Prosthetic devices are generally considered to serve occupational, recreational and cosmetic roles. Depending on the patient's activities and needs, more than one of each basic type may be needed. Alternatively, a single prosthesis may serve multiple functions. Although prosthetic devices are highly functional for many types of more proximal

limb loss and in many cases may be preferable to complex reconstructions, those currently available are poorly developed for partial and distal hand amputations. They tend to be adaptive devices, such as the Milbrandt prosthesis, acting as a thumb opposition post or hook and are customized for, and hence limited to, a specific task. Alternatively, they are primarily cosmetic (Pillet<sup>13</sup> or Life-Like prostheses) and may look very real but have little more than passive function. No active myoelectric devices are available. Furthermore, prostheses are insensate and devoid of the tactile properties of autogenous tissues required for the manipulation of small objects and fine hand function. Accordingly, prosthetic options for the partial hand amputations are generally poor and mostly limited to a cosmetic role.

Autogenous techniques described for thumb reconstruction, such as osteoplastic procedures and metacarpal lengthening, have also been applied to finger reconstruction but suffer from the same limitations of restricted mobility, inadequate dexterity, poor or absent sensibility, the absence of the tactile function, poor stability of the distal nail-pulp complex, and an unsatisfactory appearance.<sup>3,7,8</sup>

Finger reconstruction for the multiple digit amputation must provide for the basic hand functions of pinch, grasp and hook. As with thumb reconstruction, toe transplantation is considered to be the superior alternative by providing a mobile, strong, sensate and adaptive opposable unit with acceptable cosmetic results. Indeed, transfer of multiple toes to reconstruct at least 2 fingers is often

considered to be indicated and optimal.<sup>1-3,7, 8,14-16</sup>

Nonetheless, surgeons have been reluctant to use toes for finger reconstruction because of their short length, non-finger-like appearance, and limited range of motion and sensibility. These issues have implications for both hand function and patient acceptance of hand appearance, and when considered with the potential for foot morbidity are expected to be of more significance in reconstructing a hand that is missing some of its digits but retaining others. The senior author (R.T.M.) has used toe-to-finger transfer (TFT) for reconstruction of hands that were fingerless in the expectation that these concerns would not be as critical as in the hand that retains some normal fingers.

The purpose of this study was to assess the utility of TFTs for post-traumatic reconstruction in a series of fingerless hands by examining the function and morbidity of the hand and foot, and patient acceptance.

## Patients and interventions

The senior author performed 12 free vascularized TFTs in 8 patients over 12 years. All were men, and the average age at the time of transfer was 36 years (range from 25-59 yr). Three left and 5 right hands were injured with 5 dominant hands being involved.

One patient had suffered severe burns at 8 months of age and presented for reconstruction 38 years later; 1 had incurred severe frostbite injuries to all 4 extremities, resulting in multiple digit amputations; and the remaining 6 patients had industrial accidents involving crushing or de-

gloving amputations. Seven patients' injuries were Worker's Compensation Board (WCB) injuries and occurred at an average age of 33.4 years (range from 24–54 yr). Four patients had amputation injuries of all 5 digits, although 1 of these had successful thumb replantation; 3 patients had 4 finger amputations but no thumb amputation; and 1 patient had amputation of the radial 4 digits leaving the little finger intact. Hence, the hands presenting for reconstruction included 3 with amputation defects of all 5 digits, 4 with a thumb but with defects of the 4 fingers and 1 with a small finger but loss of the other 4 digits. Significant non-digital hand injuries were present in 3 patients, consisting of groin flaps in 3 patients and split-thickness skin grafts in 2.

Excluding the burn patient, the average interval between amputation and TFT was 17.2 months (range from 7.0–51.5 mo). Four of the patients also had toe-to-thumb transfers: in 1 patient 70 days before the TFT, in 1 at the same operation as the TFT, and in the other 2 at 99 days and 194 days after the TFT. Four patients had 2 TFTs. Two patients had this performed at the same operation: 1 with a conjoint transfer of the contralateral second and third toes to the ring and small fingers, respectively, and 1 with an ipsilateral second and third toe transfer to index and long fingers. The other 2 had subsequent TFTs 90 and 168 days from the first transfer (at a mean time of 3.9 mo).

Donor digits included 10 second toes and 2 third toes (as 2 combined transfers with second toes); 8 transfers were from the left foot and 4 from the right. The transfers were of ipsilateral toes in 7 and contralateral toes in 5. Recipient digits were 3 index, 5 long, 3 ring fingers and 1 little finger. Recipient ray amputation levels were at the head or distal end of the metacarpal in 4 and the proximal phalanx in 8. Osteosynthesis resulting in joint fusion was through the metacarpophalangeal (MCP) joint in 2 transfers and the proximal interphalangeal

(PIP) joint in 1. Hence, all digits but 1 had an intact transferred PIP joint, 8 of 12 had intact native MCP joints, and 2 had functioning MTP joint transfers, while the remaining 2 had osteosynthesis through the MCP.

Osteosynthesis was with interosseous wires and a temporary Kirschner wire in all, and 3 additionally had bone grafting which involved a bone peg in 1. Angular and rotatory positioning of the transferred digit to facilitate thumb opposition was undertaken in each case.

Angiography of the donor foot and recipient hand was performed in all patients, but the results did not always coincide with operative findings or vessels used for anastomosis. Significant abnormalities were present in 4 of the 8 hands. In the foot, the dominant circulation was dorsal in 7 and plantar in the other 5 transfers. Single arterial anastomoses were used in 9 transfers (including the 2 combined second and third toe transfers) and both toe vessels were used in 1. Vein grafts were required in 4 of the 11 arterial anastomoses. Three anastomoses were to palmar vessels (digital or common digital, all without vein grafts), 6 were to dorsal vessels (radial artery or princeps pollicis, 2 vein grafts required) and 1 was with 2 arterial anastomoses by vein grafts to the ulnar artery at the wrist. One dorsal venous anastomosis per digit transferred was performed in all cases.

Both donor digital nerves were coapted to recipient site nerves in all digits, although 2 digits required nerve grafts. Dorsal nerve repairs were clearly documented in 3 digits.

Tendon coaptation was to the corresponding extensor digitorum communis (extensor indicis proprius for index) and flexor digitorum profundus, with 1 flexor tendon graft required.

Skin grafts were required for closure in 4 transfers: 2 to the hand and 2 to the transferred digit. Primary donor site closure was attained in all.

Incidental procedures to improve the hand performed at the time of toe transfer included release of a

thumb MCP flexion contracture (capsulolysis and flexor pollicis longus tenolysis), a first web deepening with resection of neuroma and second and third metacarpal heads, a recipient site MCP capsulolysis and a groin flap revision. Secondary procedures included an opponsensplasty for traumatic loss, a metacarpal exostosis resection at the site of the osteosynthesis, a metacarpal rotational osteotomy to improve opposition position, 2 flexor tenolyses, and a first web deepening procedure.

One toe was lost to arterial thrombosis in a patient who had only 1 TFT, leaving 11 successfully transplanted toes on 7 patients' hands as the study population. The patients' injuries and reconstructed hands are summarized in Table 1. Only 1 of the 7 patients could not be located for follow-up assessment. The average follow-up for the 6 patients and their 9 transferred digits was 45.0 months (range from 10.9–143.7 mo).

Patient follow-up assessment consisted of objective (complications, range of motion, sensation, strength, Jebsen–Taylor functional assessment<sup>17</sup> and employment status) and subjective (hand and foot symptoms, activities of daily living, avocational function and patient satisfaction) measures of outcome.

Digital sensation was assessed in terms of moving 2-point discrimination (m2PD), pinprick, light and heavy static and moving touch sensation, and vibration sensation (30 Hz and 256 Hz).

Strength recovery was assessed by Jamar grip and key pinch strength. The absolute values were compared as a percentage of those from the contralateral hand.

The Jebsen–Taylor assessment provided a means of objectively measuring the recovery of commonly used hand activities by timing the execution of standardized tasks and comparing the results to normal values based on age, sex and preinjury hand dominance. These tasks included writing, simulated page turning, picking

up small objects, simulated feeding, stacking checkers, picking up large light objects and large heavy objects.

A subjective appraisal of patient recovery and function was attained through individual patient interviews and patient completion of a questionnaire.

Symptoms relating to the recipient hand and the donor foot were self-scored as follows: none, slight, moderate or severe. Changes in gait or footwear were also noted.

Although all patients were living and functioning independently, their functional abilities and independence in terms of self-care were assessed using an activities of daily living checklist with 50 test tasks subdivided into the following: dressing, grooming, feeding, homemaking and miscellaneous. Ability was self-scored for each activity as follows: independent, independent with difficulty, requires assistance, unable to perform or not applicable.

The patients' avocational assessment considered social and recreational function.

Patient satisfaction was assessed with respect to surgical treatment, rehabilitation therapy and overall outcome in terms of appearance and function. Results were scored as poor, fair or good.

**Results**

*Objective*

*Complications*

Recipient site complications involved failure of the toe transfer in 1 patient (8.3% of all TFTs). This patient had bilateral second toe to thumb and long ray transfers during the same operation in a very scarred hand associated with occlusion of the radial artery at the wrist requiring a 14-cm long vein graft from the ulnar artery and branches to the 2 transferred digits. There was a problem with flow intraoperatively, and the patient was brought back to the operating room on 2 occasions over the following week with arterial failure (anastomotic and vein-graft thrombosis) for revision of the anastomosis and additional vein grafting before both digits finally failed completely and were amputated. The only other vascular problems were arterial compromise in 2 patients and venous compromise in 1 patient; 2 patients were successfully treated with suture or split-thickness skin graft release on the ward and the other required operative thrombectomy and revision of the arterial anastomosis.

Donor site complications included early donor site skin slough requiring grafting in 1 patient and a hematoma needing drainage.

*Range of motion*

The average active range of motion was 59° (range from 30°–85°) at the MCP joint, 18° (range from 0°–60°) at the PIP joint, and 10° (range from 0°–20°) at the distal interphalangeal (DIP) joint (Table 2). Average total angular motion mea-

**Table 2**  
**Objective Results (Mean Values)**

Test	Result
Range of motion, °	
Metacarpophalangeal joint	59
Proximal interphalangeal joint	18
Distal interphalangeal joint	10
Total angular motion	81
Moving 2-point discrimination, no (and %)	
<15 mm*	5 (55.6)
≥15 mm	4 (44.4)
Strength, kg ipsilateral (and % of contralateral)	
Grip	10.0 (26.1)
Key pinch	5.4 (70.2)

\*Average 7.4 mm

**Table 1**  
**Patient Injuries and Reconstructions**

Patient no.	Injured hand	Dominance	Intact digits	Digits reconstructed	Amputation level	Donor toe	Fixation level
1	Right	ND	Small	Thumb Ring	P1 P1	Right, D1 Left, D2	MC P1
2	Left	ND	None	Thumb Long	P1 P1	Right, D1 Left, D2	P1 P1
3	Right	D	Thumb	Index Long	P1 P1	Left, D2 Right, D2	PIP (fused) P1
4	Left	ND	None	Thumb Index Long	P1 P1 P1	Left, D1 Left, D2 Left, D3	P1 P1 P1
5	Left	D	Replanted thumb	Ring	MC	Left, D2	MCP (fused)
6	Right	D	Thumb	Index Long	P1 P1	Right, D2 Left D2	P1 P1
7*	Right	D	Thumb	Ring Small	MC MC	Left, D3 Left, D2	MC MC

\*Could not be located for follow-up.  
ND = nondominant, D = dominant, P = phalangeal, MC = metacarpal, D = digit, PIP = proximal interphalangeal, MCP = metacarpophalangeal.



sured 81° (range from 55°–120°). In all but 1 patient (no. 5) the native MCP joint had remained intact after the injury and, although abnormal, the MCP contributed an average of 75.2% of the final total angular motion compared with 14.5% and 10.3% for the transferred toe PIP and DIP joints, respectively, in patients having all 3 joints functional (Fig. 1). The patient with MCP fusion (no. 5) had the greatest PIP range of motion, which may reflect obligate concentration of the angular motion caused by tendon excursion at the PIP level whereas in the other patients it occurred more easily at the MCP level.

#### Sensation

Four (44.4%) of the 9 TFTs had no effective m2PD (>15 mm); the

other 5 (55.6%) had m2PD <15 mm (mean 7.4 mm) (Table 2). Patients with no m2PD recovery were all older than 35 years (mean 47.0 yr) whereas those with return of m2PD were all younger than 35 years (mean 27.7 yr). All digits recovered pinprick, heavy movement, light touch and course vibration sensation.

#### Strength

One patient with bilateral digit loss, but unilateral reconstruction, used a prosthesis on the contralateral extremity, obviating a percentage comparison and excluding him from the average. The average grip strength was 10.0 kg (range from 5.5–20.0 kg), and the average percent of the contralateral hand was 26.1% (range from 12.7%–63.0%) (Table 2). The average key pinch strength was

5.4 kg (range from 4–11.5 kg), and the average percent of the contralateral hand was 70.2% (range from 35.0%–140%) (Table 2). Hence, all hands demonstrated recovery of the major functions of grip and key pinch, but recovery of key pinch was better than grip strength with respect to the contralateral uninjured hand. Of note, with the small patient numbers, absolute and relative percentage recovery did not appear to relate to the dominance of the reconstructed hand, digit ray position or whether thumb reconstruction had also been required. However, recovery was generally better if at least 2 fingers (or TFTs) were present.

#### Jebesen–Taylor functional assessment

The 9 TFTs (6 patients) were eval-

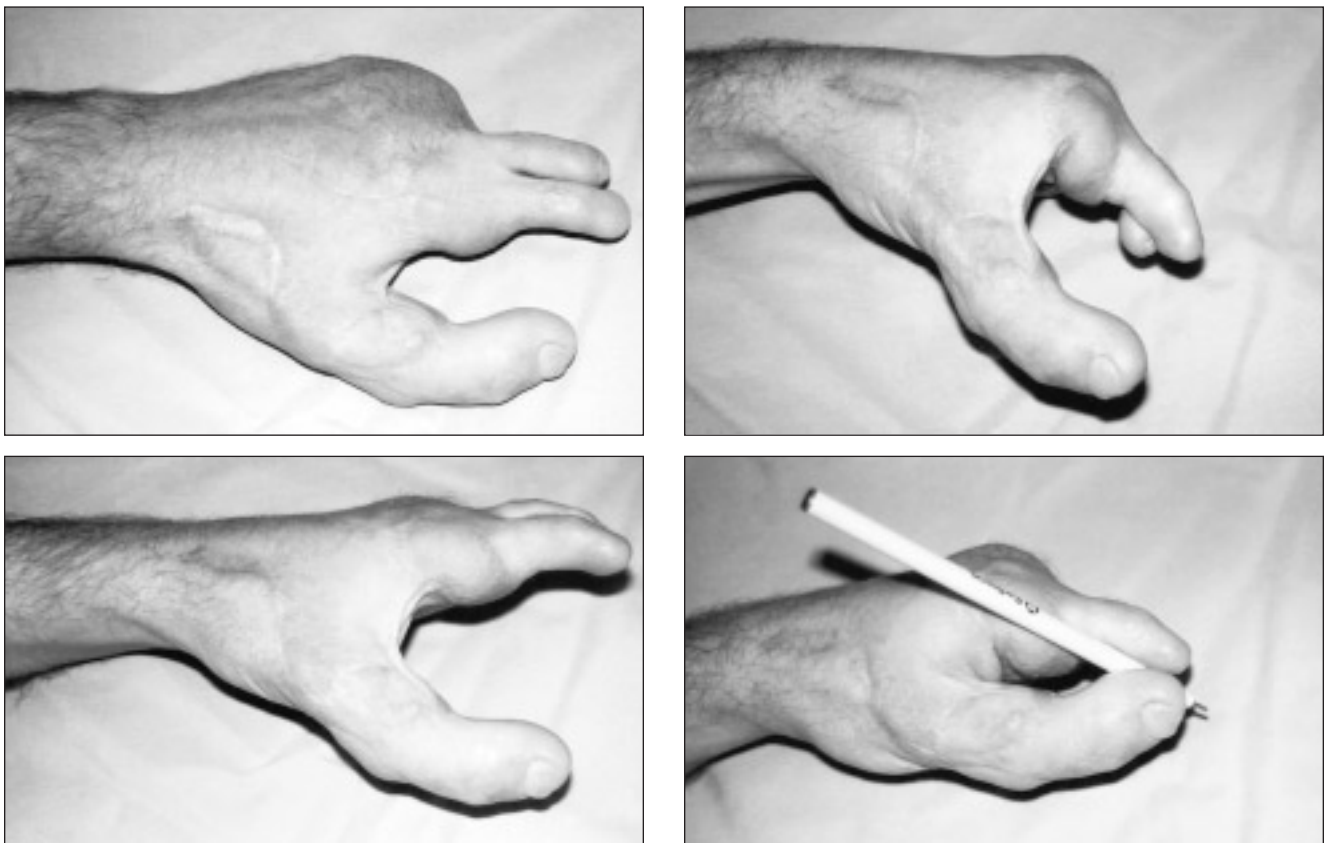


FIG. 1. A patient who suffered severe frostbite and lost all the digits from both hands and multiple toes from the right foot underwent reconstruction of the left-hand digits using transfers of the great toe to thumb as well as the second and third toe to index and long fingers respectively (top left). He recovered a very functional range of motion (top right). Note that after reconstruction most of the finger flexion occurs at the native metacarpophalangeal joint (bottom left). Despite an average appearance, he had an excellent functional result (bottom right).

uated according to the Jebsen-Taylor<sup>17</sup> assessment of hand function.

The small number of patients and variety of reconstructions make statistical statements regarding functional recovery with respect to hand dominance and reconstruction impossible. Generally, results were below normal values with few exceptions (Table 3). Also, although outlying values skewed the mean in some categories, the results tended to show that, except for lifting small and large light objects, nondominant hand function recovered closer to normal values than dominant hand function. The patient with replantation of the thumb and a single toe transfer to the ring finger with MCP fusion (no. 5) most commonly had outlying test results supporting the need for the presence of more than 1 digit. Of the 3 patients who had suffered dominant hand injuries, all changed hand dominance. However, 1 of the patients reverted to preinjury dominance after reconstruction. Most significantly, all of the patients could perform every task with the reconstructed hand (Fig. 1), which they could not have without the TFTs (a fingerless hand) or with a single prosthetic device.

#### Employment

Five of the 6 patients were WCB injuries, yet all returned to gainful employment after rehabilitation. One returned to his original job as a ma-

chinist; the remainder assumed more sedentary occupations.

#### Subjective

##### Hand and foot symptoms

Hand symptoms were not always specifically related to the transferred digit and could not be definitively separated from the residua of the original injury. Symptoms of pain, hypoesthesia and paresthesia were nonexistent in 4 patients and slight to moderate but not functionally incapacitating in 2 patients. Cold intolerance was reported to be moderate to severe in 5 patients.

Foot symptoms of pain and cold intolerance were uncommon, being absent in 4 of the 6 patients and only slight in the other 2. Three patients felt that there was some subjective change in their gait. One had to change shoe type and 1 required an orthotic insert.

##### Activities of daily living

Functional independence was similar between patients, and the average scores for the activities of daily living were as follows: independent — 82.6%; independent with difficulty — 10.0%; requires assistance — 3.2%; and unable to perform — 4.2%. Overall, the patients functioned quite well, with difficulty most commonly being associated

with tasks demanding high bimanual dexterity or primary dependence on the reconstructed hand for execution, such as threading a needle or sewing with the reconstructed hand.

##### Avocational function

Although a prereconstruction assessment was not available for comparison, all patients reported marked improvement after their reconstruction. Four of the 6 patients were conscious of the appearance of their reconstructed hand (Figs. 1 and 2) in terms of perceived social acceptance. None related any new interpersonal difficulties with spouse or family relating to the reconstruction.

##### Patient satisfaction

The patients were very satisfied with their surgical care (all 6 scored good) and rehabilitative care (5 scored good) and their overall final outcome (6 scored good).

#### Discussion

The morphologic similarities between toes, fingers and thumbs are obvious, but whereas the great toe and thumb have almost identical anatomic characteristics, the other 4 toes are considerably shorter than the fingers, making them best suited for reconstruction of a partial digital defect. The difference in length can also

Table 3

#### Jebsen-Taylor Functional Assessment\*

Patient no.	Dominance of reconstructed hand	Writing	Page turning	Simulated feeding	Stacking checkers	Pick up		
						Small, light	Large, light	Large, heavy
1	Nondominant	33	7	8	5	10	4	4
2	Nondominant	37	5	13	5	10	5	4
3	Dominant	37	7	11	3	9	5	4
4	Nondominant	27	4	8	4	13	8	6
5	Dominant	27	23	18	10	7	5	7
6	Dominant	14	4	8	3	8	4	4
Normal male, age 20-59 yrf	Dominant	12.2 (3.5)	4.0 (0.9)	6.4 (0.9)	3.3 (0.7)	5.9 (1.0)	3.0 (0.4)	3.0 (0.4)
	Nondominant	32.3 (11.8)	4.5 (0.9)	7.9 (1.3)	3.8 (0.6)	6.2 (0.9)	3.2 (0.4)	3.1 (0.4)

\*Values are in seconds.

†Mean (and standard deviation)

be problematic when adjacent digits remain intact. The metatarsal phalangeal joint also tends to extend better than it flexes and has a smaller range of motion and the interphalangeal joints of the transferred second and third toes tend to resume their usual somewhat flexed position after transplantation.<sup>7</sup> Hence, toes are clearly not fingers, but as others have noted, "when there is nothing even a little is a lot."<sup>8</sup> Concern has been raised over the potential for compromising the foot, especially if multiple toes are transferred from the same side.<sup>18,19</sup> The indications and appropriateness of toe transfer for finger reconstruction vary in the literature. Whereas second toe or multiple toe transplantations to create an ulnar post for thumb opposition in a proximal 4-finger amputee is the clearest indication, transfers for less severe finger losses have been described and are more controversial.<sup>7,20-22</sup> Nonetheless, transfer may be indicated in subtotal finger amputations to restore tripod pinch or the breadth and grip of the hand, and occasionally in special circumstances (e.g., musicians) for less significant deficits.<sup>20,23</sup>

Accordingly, the decision to proceed with TFT needs to be individualized and founded on an understanding of both the outcome and the expected morbidity. It was because of concern regarding functional gain relative to appearance, acceptability and foot morbidity that the senior author limited TFTs to patients with fingerless hands. This study was

undertaken to assess the utility of the technique by examining the resulting function and morbidity of the hand and foot, and patient acceptance.

The results of range of motion measurement (59° at the MCP, 18° at the PIP and 10° at the DIP with an average total angular motion of 81°) are in keeping with those reported in the literature.<sup>3,7,8,14,15,18,23</sup> In our series, 75.2% of the total angular motion for the digit reconstructed through the proximal phalanx occurred at the native MCP joint, whereas only 34.8% occurred through the interphalangeal joints of the transferred toes. These results indicate that the transferred toes' active range of motion is generally poor with respect to normal digits, underlining the need to preserve the base of the proximal phalanx with its intact extensor hood, sagittal band and collateral ligament attachments whenever possible at the time of revision amputation.

Assessment of sensation demonstrated uniform recovery of pinprick and light touch sensibility. Of the 9 toes transferred, 5 recovered m2PD (average 7.4 mm). The sensibility results in our series segregated according to patient age younger or older than 35 years, as noted by others.<sup>23</sup> Obviously the status of the native nerves, degree of hand trauma, level of the coaptation and the need for nerve grafting may also influence the results.<sup>8</sup> Generally, 60% of digits will get less than 15 mm of 2-point discrimination at 2 years.<sup>3,24,25</sup> Nonetheless,

it is significant that in our series 4 of the 6 patients had no complaints with respect to sensory loss, suggesting that sensation recovery merits less concern.

Grip strength averaged 26.1% of the contralateral hand, whereas pinch strength was significantly better, averaging 70.2% of the contralateral hand, again commensurate with results reported in the literature.<sup>3,14</sup> Grip strength was better in those hands with 2-finger reconstructions. This supports the reconstructive goal of at least 2 fingers. Notably, toe shortness caused no subjective or objective functional compromise.

The Jebsen-Taylor functional assessment of commonly used hand activities found that reconstructed nondominant hands generally were restored closer to normal values than reconstructed dominant hands. Maintenance of dominance is variably reported, has been related to the severity of the injury<sup>3,18</sup> and was seen in only 1 of our patients, and only after reconstruction. Although the timed task results in this series might be considered poor versus normal, what is clearly most significant is that all of the patients could perform all of the tasks with their reconstructed hands.<sup>26</sup> Evaluation of employment status demonstrated excellent functional recovery with all 6 patients returning to work. We believe that no other digital reconstruction would have allowed this.

Hand symptoms tended to be mild with the exception of cold in-

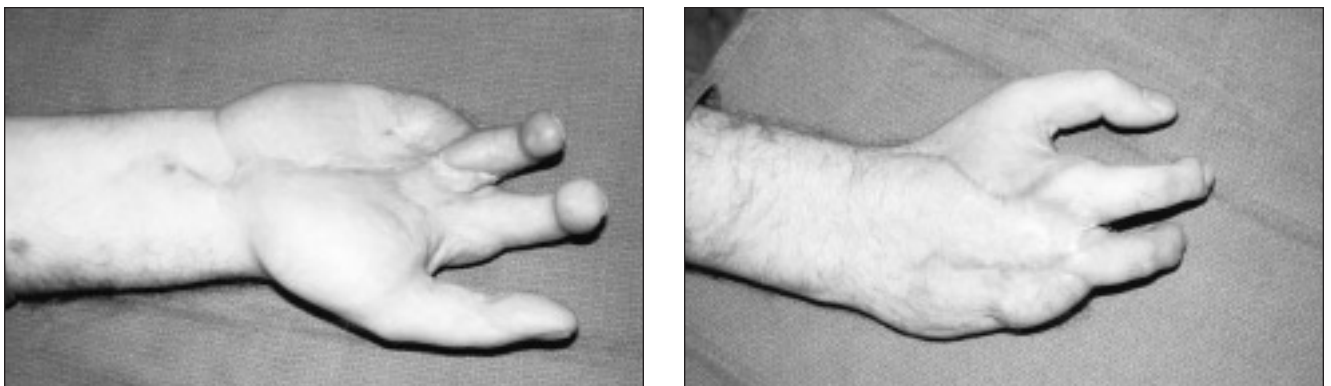


FIG. 2. Toe transfers to the index and long fingers demonstrating a good esthetic result.

tolerance that was moderate to severe in 5 patients. This particular symptom has been reported to be of variable severity in a number of series.<sup>3,14,15,18,23</sup> It may reflect the different climates from which the patient populations originate. Furthermore, separating this particular symptom from others and attributing it to the toe transfer alone is hard to resolve in the setting of a major hand crush and amputation injury where cold sensitivity is common.

Foot symptoms also tended to be mild, although 3 patients in this series reported subjective changes in their gait, and 2 of these required shoe modification. Of these 3 patients, 1 had suffered severe frostbite to his hands and feet with loss of multiple digits. This patient also had hand reconstruction with a conjoined second and third toe transfer for fingers and a subsequent great toe-to-thumb transfer all from the same foot. The second patient required a change in his shoe type because of symptoms in the foot that had donated its great toe, including part of the MCP joint, for thumb reconstruction and not the foot that had donated its second toe for finger reconstruction. The third patient's subjective change in gait appeared to result from postoperative peroneus tendinitis. Other studies have also noted that in patients with 2 or more toes transferred from the same foot, functional and aesthetic morbidity is more common.<sup>7,8,14-16,18,19</sup>

Although preoperative tests were not available for comparison, overall function after reconstruction was very good, with patients performing 92.6% of the activities of daily living test tasks without assistance. A similar proportion noted that their reconstructed hands drew attention in public, particularly if any normal fingers were present. Despite this, patient satisfaction was very high in our study and in others, with all patients feeling that the improvement in hand function and appearance after reconstruction far outweighed the morbidity.<sup>7,18</sup>

Restoration of basic pinch, grasp and hook function to the fingerless hand requires optimal positioning of the transferred digit(s) for the thumb to work with. This must be individualized because hand and thumb function may not be normal and procedures to improve this may be necessary. Consequently, preoperative planning is critical to locate the transplanted digit in the most advantageous position relative to the function of the hand elements remaining (thumb or partial digit amputation stumps, or both) in terms of length, rotation, angulation and ray position. Plasticine clay models are invaluable in this preoperative assessment and planning. Other considerations are the relative length of the digit transferred and the cascade of the reconstructed fingers, which must position the ulnar-most digits ahead of the radial digits for thumb opposition. The fact that toe range of motion will be considerably less than normal has implications too and is probably reflected in the greater relative restoration of key pinch than grip strength. Whereas ulnar positioning takes advantage of the greater mobility of the ulnar carpometacarpal joints and allows gripping of larger objects, series reported in the literature most commonly positioned digits on the long ray and slightly less frequently on the index or ring ray.<sup>3,4,8,18</sup> Hence, it seems prudent to position the toe on the third ray to maintain the potential for good pinch function but at the same time achieve some hand breadth for grip, with a second transfer to the second or fourth ray, depending on thumb and recipient ray mobility. Accordingly, optimal positioning needs to be individualized to the remaining hand elements and their function, particularly the length and mobility of the thumb and any remaining proximal phalanges, as well as to the patient's needs. Secondary procedures to improve the function of the remaining elements (e.g., first web deepening) or revise the transferred toe (e.g., rotational

osteotomy or tenolysis) may be required to optimize final function.

For a patient with no fingers and a functional thumb, the presence or reconstruction of 2 or 3 fingers is ideally necessary to restore the essential hand functions of pinch, hook and grasp.<sup>16</sup> As in our series, provision of at least 2 mobile sensate digits allows the advantage of tripod pinch over enhanced lateral stability for hook grip, a widened hand span for grasping larger objects, enhanced power grip, augmented precision handling and overall hand prehension, and improved cosmetic acceptability.<sup>15,24</sup> Multiple digit reconstruction may be undertaken simultaneously or sequentially. Proponents of double simultaneous transplants (usually bilateral second toes) believe this procedure is superior because the patient undergoes and has to recover from only one operation, total operating room time, rehabilitation time and total cost are reduced, return to work is sooner and no increase in morbidity from bilateral foot procedures has been noted.<sup>3,7</sup> Conjoined second and third toe transfer is another option that some feel is indicated for reconstruction of digits amputated proximal to the web spaces when the remaining fingers are no longer than the small finger.<sup>14,15</sup> Potential advantages over combined simultaneous bilateral second toe procedures are said to include the following: only one microsurgical procedure, less operative time, risk and expense, only a single set of recipient vessels, and a solitary donor site that allows for more rapid postoperative ambulation.<sup>15</sup> The major disadvantage of conjoined transfers over transfers from separate feet involves greater foot morbidity, as evidenced by prolonged wound healing, standing and ambulatory discomfort, and migration of the fourth toe toward the great toe.<sup>14,15,24</sup>

In this series, 2 of the original patients had conjoined second and third toe transfers. One was lost to follow-up but had early problems in



the first year with foot discomfort after prolonged standing. The other has done well, having good hand function and no major foot morbidity despite suffering significant frostbite at the primary injury. The other 2 patients with 2 toe transfers had them performed sequentially with bilateral second toe transfers, an average of 3.9 months apart. We prefer this approach. Sequential transfer allows optimal planning and independent positioning of each digit transfer according to the other hand elements, including any other transferred toes, which is critical to success but more limited with simultaneous and especially conjoined toe transfers that also limit web depth. There is also less potential for significant bilateral or unilateral foot morbidity than with conjoined or simultaneous bilateral harvest, and sequential transfer does not impose the same high demand on resources as simultaneous transfers, which require multiple surgical teams and prolonged operative times. Finally, all is not risked at one surgical procedure. The timing of the sequential procedures is important and must not unduly delay the rehabilitative process but must allow adequate healing from the first procedure plus establishment of a stable rehabilitative state such that an accurate assessment of the positional needs for the second transfer can be determined while the risk for loss of rehabilitative ground in the other digit is minimized.

Although it is evident that transferred toes do not match fingers, in that focal function might be considered poor in terms of total angular motion, m2PD, strength and timed task completion, what is most significant is that the reconstructed hands are returned to useful, sensate, adaptable and versatile functional units with very good global function as evidenced by the ability to do the timed tasks, 93% independence in activities of daily living, 100% return to work and very high patient satisfaction.

The main reasons most North American surgeons and patients have been reluctant to proceed with TFT likely relate to concerns that digit length will be inadequate for function (especially grip of large objects) and that appearance will be unacceptable. However, this has not been the case, and the tremendous functional gains readily override the cosmetic concerns. Although a comparative study is not presented, given the other options available, an individualized and well-planned reconstruction of the fingerless hand with TFTs provides excellent restoration of hand function with acceptable morbidity.

#### References

- O'Brien BM, Brennen MD, McLeod AM. Simultaneous double toe transfer for severely disabled hands. *Hand* 1978;10(3):232-40.
- Lichtman DM, Ahbel DE, Murphy RB, Buncke HJ Jr. Microvascular double toe transfer for opposable digits — case report and rationale for treatment. *J Hand Surg [Am]* 1982;7(3):279-83.
- Gordon L, Leitner DW, Buncke HJ, Alpert BS. Hand reconstruction for multiple amputations by double microsurgical toe transplantation. *J Hand Surg [Am]* 1985;10(2):218-25.
- Simonetta C. Reconstruction of the thumb by tube pedicle, bone graft and island flap. In: Reid DA, Gosset J, editors. *Mutilating injuries of the hand, no. 3*. New York: Churchill Livingstone; 1979. p. 95-8.
- Matev IB. Thumb reconstruction through metacarpal bone lengthening. *J Hand Surg [Am]* 1980;5(5):482-7.
- Brown H, Welling R, Sigman R, Flynn W, Flynn JE. Phalangizing the first metacarpal. *Plast Reconstr Surg* 1970;45(3):294-7.
- Buncke MG, Buncke HJ, Oliva A, Lineaweaver WC, Siko PP. Hand reconstruction with partial toe and multiple toe transplants. *Clin Plast Surg* 1992;19(4):859-70.
- Leung PC. Finger reconstruction using toe transplantation. *J Hand Surg [Br]* 1986;11(1):20-2.
- Buncke HJ Jr, Buncke CM, Schultz WP. Immediate Nicoladoni procedure in the rhesus monkey, or hallux-to-hand transposition utilizing microminature vascular anastomoses. *Br J Plast Surg* 1966;19(4):332-7.
- Cobbett JR. Free digital transfer: report of a case of transfer of a great toe to replace an amputated thumb. *J Hand Surg [Br]* 1969;51(4):677-9.
- Buncke HJ Jr, McLean DH, George PT, Creech BJ, Chater NL, Commons GW. Thumb replacement: great toe transposition by microvascular anastomosis. *Br J Plast Surg* 1973;26(3):194-201.
- O'Brien BM, MacLeod AM, Sykes PJ, Donahoe S. Hallux-to-hand transfer. *Hand* 1975;7(2):128-33.
- Pillet J. Esthetic hand prostheses. *J Hand Surg [Am]* 1983;8(5 Pt 2):778-81.
- Wei FC, Chen HC, Chaung CC, Noordhoff MS. Simultaneous multiple toe transfers in hand reconstruction. *Plast Reconstr Surg* 1988;81(3):366-77.
- Wei FC, Colony LH, Chen HC, Chuang CC, Noordhoff MS. Combined second and third toe transfer. *Plast Reconstr Surg* 1989;84(4):651-61.
- Zhong-jia Y. Reconstruction of the digitless hand. *J Hand Surg [Am]* 1987;12(5 Pt 1):722-6.
- Jebsen RH, Taylor N, Trieschmann RB, Trotter MJ, Howard LA. An objective and standardized test of hand function. *Arch Phys Med Rehabil* 1969;50(6):311-9.
- Frykman GK, O'Brien BM, Morrison WA, MacLeod AM. Functional evaluation of the hand and foot after one-stage toe-to-hand transfer. *J Hand Surg [Am]* 1986;11(1):9-17.
- May JW, Smith RJ, Peimer CA. Toe-to-hand transfer for thumb reconstruction with multiple digit aplasia. *Plast Reconstr Surg* 1981;67(2):205-13.
- Koshima I, Etoh H, Moriguchi T, Soeda S. Sixty cases of partial or total toe transfer for repair of finger losses. *Plast Reconstr Surg* 1993;92(7):1331-8.
- Wei FC, Epstein MD, Chen HC, Chaung CC, Chen HT. Microsurgical reconstruction of distal digits following mutilating hand injuries: results in 121 patients. *Br J Plast Surg* 1993;46(3):181-6.
- Gu YD, Zhang GM, Cheng DS, Yan JG, Chen XM. Free toe transfer for thumb and finger reconstruction in 300 cases. *Plast Reconstr Surg* 1993;91(4):693-700.
- Foucher G, Moss AL. Microvascular second toe to finger transfer: a statistical analysis of 55 transfers. *Br J Plast Surg* 1991;44(2):87-90.
- Wei FC, Chen HC, Chuang CC, Noordhoff MS. Reconstruction of a hand, amputated at the metacarpophalangeal level, by means of combined second and third toes from each foot: a case report. *J Hand Surg [Am]* 1986;11(3):340-4.
- Lister GD, Kalisman M, Tsai TM. Reconstruction of the hand with free microvascular toe-to-hand transfer: experience with 54 toe transfers. *Plast Reconstr Surg* 1983;71(3):372-86.
- Stern EB. Stability of the Jebsen-Taylor Hand Function Test across three test sessions. *Am J Occup Therapy* 1992;46(7):647-9.