

SOFT-TISSUE CASE 34. PRESENTATION

A 55-year-old woman with no significant medical history was admitted to hospital with a 3-day episode of severe pain in the right upper abdominal quadrant. She denied any postprandial pain. For 2 months she had been treated for an upper respiratory tract infection with

cough by a local general practitioner.

On examination there was a vague tender mass in the right upper quadrant. There was no rebound tenderness. She was afebrile and her leukocyte count was $14 \times 10^9/L$. Her hemoglobin level was 117 g/L and results of liver function tests were nor-

mal. Ultrasonography of the biliary tree was suboptimal because of numerous bowel gas shadows. Magnetic resonance imaging of the upper abdomen was done (Figs. 1 and 2).

What would be your diagnosis?

For the answer and discussion see page 306.

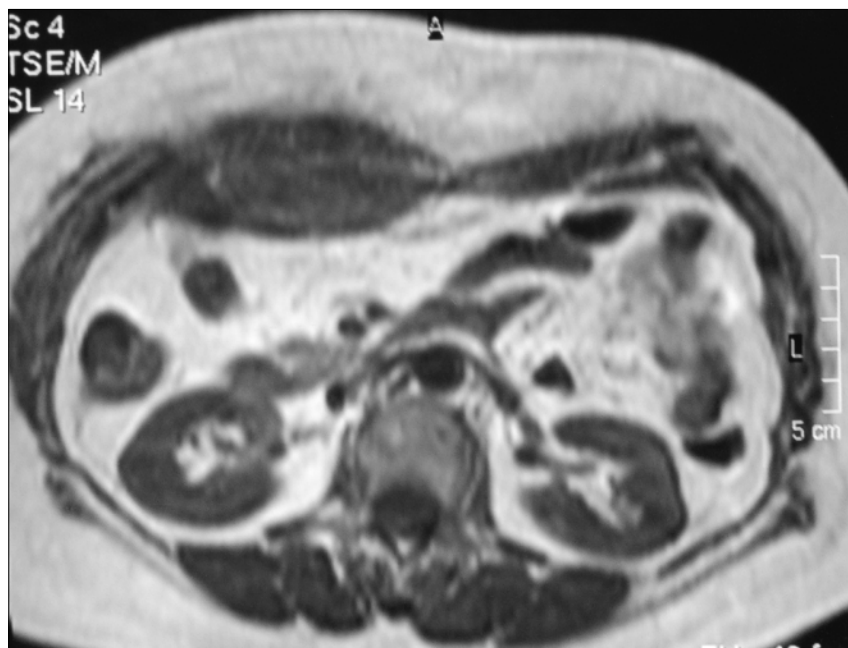


FIG. 1

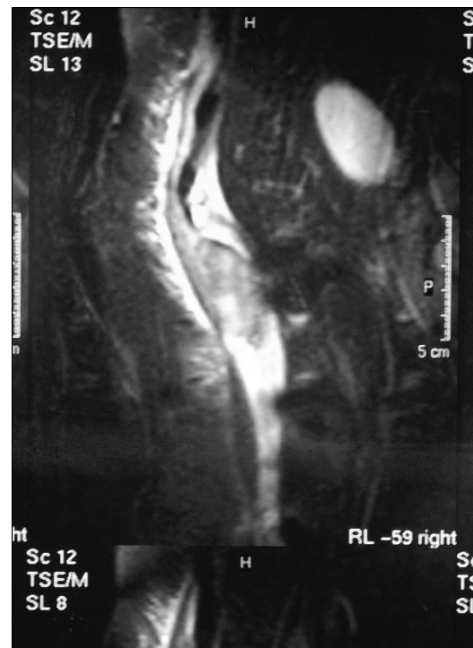


FIG. 2

Section Editor: Lawrence A. Stein, MD

Submitted by Ronald Tam, MD, Attending Specialist Surgeon, and Michael P.Y. Lee, MB BS, Resident Physician, Canossa Hospital, Hong Kong

Submissions to Radiology for the Surgeon, soft-tissue section, should be sent to Dr. Lawrence A. Stein, Department of Radiology, Royal Victoria Hospital, 687 Pine Ave. W, Montreal QC H3A 1A1.

Correspondence to: Dr. Ronald Tam, Attending Specialist Surgeon, Canossa Hospital, 1 Old Peak Rd., Hong Kong

© 2000 Canadian Medical Association