

Soft-tissue case 39. Presentation

A 76-year-old woman presented with vaginal discharge, lower abdominal pain and changes in her bowel habit. Computed tomography of the pelvis was carried out and the findings are shown in Fig. 1.

What does the scan show and what are the implications?

For the answer and discussion see [page 228](#).

Section Editor: Lawrence A. Stein, MD
Submitted by Kirsten S. Hindle, MB BS,*
and Andy Huang, MB ChB,†

*Department of Surgery John Radcliffe Hospital, Oxford, UK, and †Department of Academic Surgery, Chelsea & Westminster Hospital, London, UK

Submissions to *Radiology for the Surgeon*, soft-tissue section, should be sent to Dr. Lawrence A. Stein, Department of Radiology, Royal Victoria Hospital, 687 Pine Ave. W, Montreal QC H3A 1A1.

© 2001 Canadian Medical Association

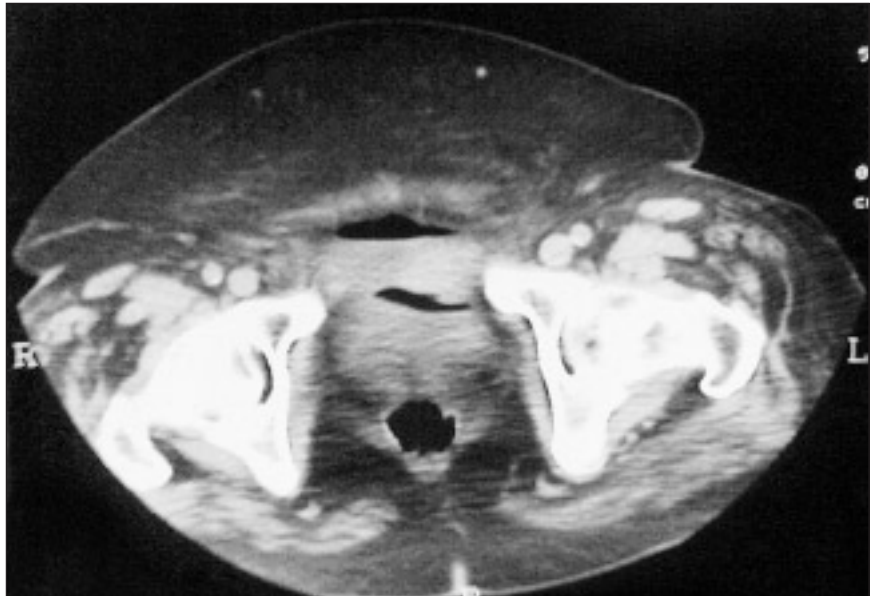


FIG. 1.

Correspondence to: Mr. A. Huang, 40 York Terrace E, Regent's Park, London NW1 4PT, UK; fax 44 20 7486-0883, andyhuang@talk21.com