

## CASE NOTE

## Carcinoma in the fourth part of the duodenum

Sampath P. Kumar, MB BS, MS  
Addala Pavan Kumar, MB BS, MS

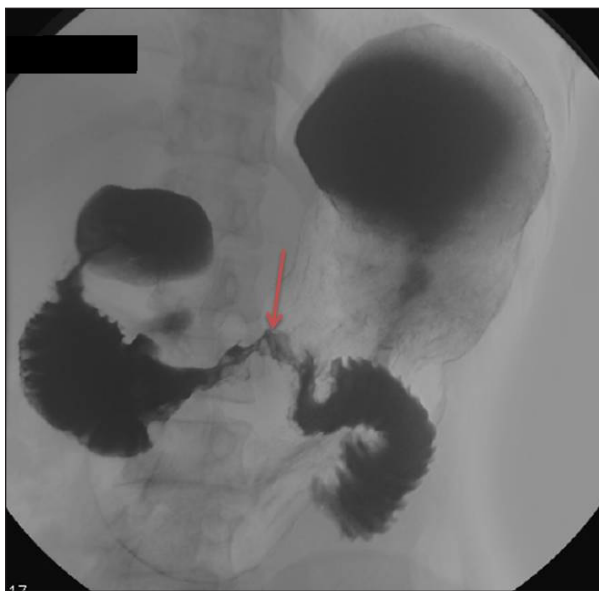From the Department of Surgery,  
Kasturba Medical College, Manipal  
University, Manipal, Karnataka, India

**Correspondence to:**  
Dr. A. Pavan Kumar  
Department of Surgery  
Kasturba Medical College Hospital  
Manipal University  
Manipal, Karnataka – 576104  
India  
dr.addala@gmail.com

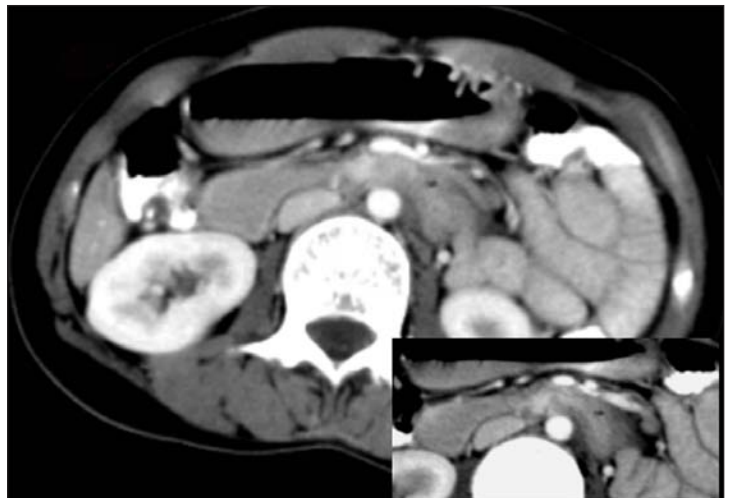
**C**ancer of the small intestine makes up 2% of all malignant tumours of the gastrointestinal tract, with 40% of them being adenocarcinomas.<sup>1</sup> Of these adenocarcinomas of the small intestine, 45%–55% lie within the duodenum.<sup>2</sup> Because the condition is rare, specific signs and symptoms are lacking. This can lead to a long interval between the start of the cancerous lesion and clinical presentation, making diagnosis and treatment all the more challenging. We report one such case and provide a brief review of the literature.

### CASE REPORT

A 28-year-old woman presented with an 8-month history of gastritis and increasingly frequent vomiting immediately after food intake. She also described having lost a substantial amount of weight over 2 months. On examination, her upper abdomen was distended and there was visible peristalsis. There was no jaundice or significant lymphadenopathy. An esophagogastro-duodenoscopy showed narrowing of the lumen at the junction of third and fourth parts of the duodenum (Fig. 1), with an apparently normal mucosa. A blind biopsy of tissue from the junction was sent for histopathological examination. Considering her age and medical history, we made a provisional clinical diagnosis of benign stricture and requested a barium meal examination to determine the extent of the lesion and to plan surgery. Meanwhile, histopathology results reported a moderately differentiated adenocarcinoma



**Fig. 1.** Esophagogastroduodenoscopy shows narrowing (arrow) at the junction of the third and fourth parts of the duodenum.



**Fig. 2.** Computed tomography scan shows narrowing of the third and fourth parts of the duodenum (inset image).

of the duodenum. To assess the operability of the lesion, the patient underwent abdominal computed tomography (CT). This showed a short segment of narrowing at the junction of the third and fourth parts of the duodenum without any clinically important lymphadenopathy or invasion into the surrounding structures (Fig. 2). Intraoperatively, we identified a mass lesion in the fourth part of the duodenum, starting at the junction of the third and fourth parts. We found no significant lymphadenopathy intra-abdominally. We did a segmental resection of the mass lesion. The patient's postoperative period was uneventful, and she was discharged on the tenth day after surgery. We offered her a trial of adjuvant chemotherapy, but she refused.

## DISCUSSION

Of duodenal adenocarcinomas, 45% arise from the distal portion (third and fourth parts), 40% from the second part and 15% from the first part of the duodenum;<sup>3</sup> these percentages parallel the length of each part of the organ.

The most common clinical features at initial presentation are abdominal pain, anemia, bowel obstruction, weight loss, jaundice, gastrointestinal bleeding, abdominal mass, bowel perforation and enterostomal ulcer. Owing to the lack of specific symptoms and signs, duodenal adenocarcinoma is associated with a delayed diagnosis and poor prognostic and survival outcomes. Awareness and use of appropriate imaging modalities are essential when evaluating patients with the signs and symptoms described. Upper gastrointestinal tract series and esophagogastroduodenoscopy seem to be the most accurate diagnostic modalities for small-bowel carcinomas. In the preoperative evaluation of the nodal status and the extent of invasion of the surrounding structures, CT and magnetic resonance imaging may be useful. As for any malignant lesion in the gastrointestinal tract, the emergent indications for surgery are bowel obstruction, gastrointestinal bleeding and bowel perforation. According to the literature, segmental resection of these tumours generally correlates with a better overall survival than a Whipple procedure,<sup>4</sup> though some studies showed a better prognosis for patients who underwent a modified Whipple procedure.<sup>5</sup> This can be attributed

to improved understanding of the procedure and postoperative management of patients and to more sophisticated technology and protocols in the intensive care units. Palliative procedures include gastric bypass, diagnostic laparoscopy, feeding jejunostomy, biliary bypass and enteric bypass. The role of adjuvant therapy in the treatment of patients with small-bowel adenocarcinoma remains ill-defined. Most studies have not found that adjuvant therapy provides a significant survival benefit.<sup>5</sup> Pathologic features, including involved tissue at the surgical margins, extramural venous spread, involved lymph nodes, poor tumour differentiation, depth of tumour invasion, distant metastasis and a history of Crohn disease, are of major prognostic importance in small-bowel adenocarcinoma.<sup>5</sup> The most common sites of recurrence are the liver, lungs and peritoneum.

In our patient's case, after we confirmed the diagnosis, taking into account the pathology report, lumen size, extent of narrowing shown on barium meal examination and the operability status shown by CT, we performed a segmental resection of the mass lesion. Intraoperatively, related lymph-node groups are not clinically important. Considering the age of our patient, the tumour-free surgical margins, tumour grade and noninvasiveness of the lesion, we expect a good prognosis and survival. We have not considered any adjuvant therapy because our patient's tumour was completely resected and there was no metastatic spread.

**Competing interests:** None declared.

## References

1. Johnson AM, Harman PK, Hanks JB. Primary small bowel malignancies. *Am Surg* 1985;51:31-6.
2. Gibbs JF. Duodenal adenocarcinoma. Is total lymph node sampling predictive of outcome? *Ann Surg Oncol* 2004;11:354-5.
3. Coit DG. Cancer of the small intestine. In: DeVita VT Jr, Hellman S, Rosenberg SA, editors. *Principles and practice of oncology*. Philadelphia (PA): Lippincott Williams & Wilkins; 2001. p. 1204-6.
4. Barnes G Jr, Romero L, Hess KR, et al. Primary adenocarcinoma of the duodenum: management and survival in 67 patients. *Ann Surg Oncol* 1994;1:73-8.
5. Abrahams NA, Halverson A, Fazio VW, et al. Adenocarcinoma of the small bowel: a study of 37 cases with emphasis on histologic prognostic factors. *Dis Colon Rectum* 2002;45:1496-502.