

CASE NOTE

A rare complication of cardiopulmonary resuscitation

Dan T. Kottachchi, BSc, MSc, MD*
Jihao Dong, BMath[†]
Susan Reid, BA, MD[‡]

From the *Department of Internal Medicine, [†]Michael G. DeGroote School of Medicine and [‡]Department of General Surgery, McMaster University, Hamilton, Ont.

Accepted for publication
Jul. 25, 2007

Correspondence to:
Dr. S. Reid
McMaster Medical Centre
Rm. 2F, 1280 Main St. W
Hamilton ON L8S 4L8
fax 905 527-1700
reid@mcmaster.ca

Chest compressions during cardiopulmonary resuscitation (CPR) can be traumatic to patients. Sternal fractures occur in 1 of 5 resuscitation attempts, and costal fractures occur in 1 of 3; two-thirds of patients with costal fractures have 3 or more fractures in adjacent ribs.¹ We report a rare complication of CPR in which the patient experienced 2 rib fractures associated with herniation of the lung parenchyma and pneumothorax.

CASE REPORT

While in hospital, a 74-year-old man with known grade 3 esophageal varices from portal vein thrombosis experienced an asystolic cardiac arrest after a massive variceal hemorrhage. After about 2.5 minutes of CPR, his condition stabilized. The medical team placed him on mechanical ventilation and transferred him to the intensive care unit, where he remained clinically stable with no evidence of ongoing upper gastrointestinal blood loss. Findings of preliminary investigations, including chest radiography, were normal. About 1 week after his cardiac arrest, while he was still on mechanical ventilation, a palpable crepitus on the left side of the sternum to the midaxillary line was noted, and repeat chest radiography demonstrated subcutaneous emphysema in that area but no obvious pneumothorax.

Contrast-enhanced computed tomography (CT) showed 2 left rib fractures and herniation of the lung parenchyma through one of the fractures (Fig. 1) along with a left-sided pneumothorax (Fig. 2). These findings were attributed to the aggressive CPR carried out at the time of cardiac arrest. The patient

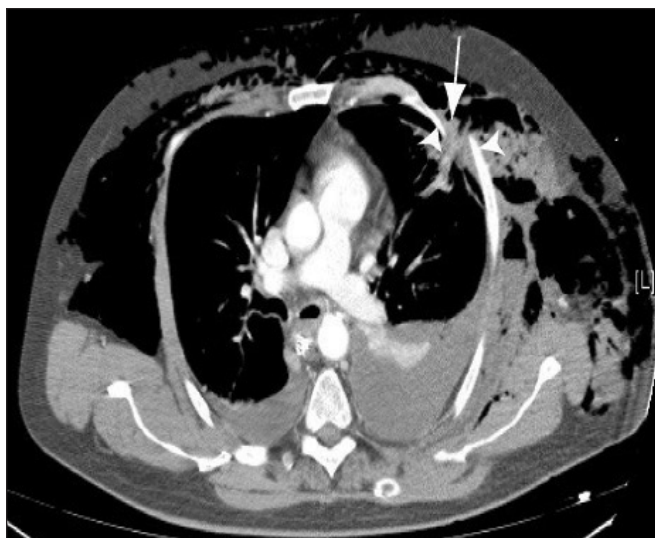


Fig. 1. Computed tomography scan (bone window) showing 2 rib fractures (white arrowheads) and lung herniation (white arrow).

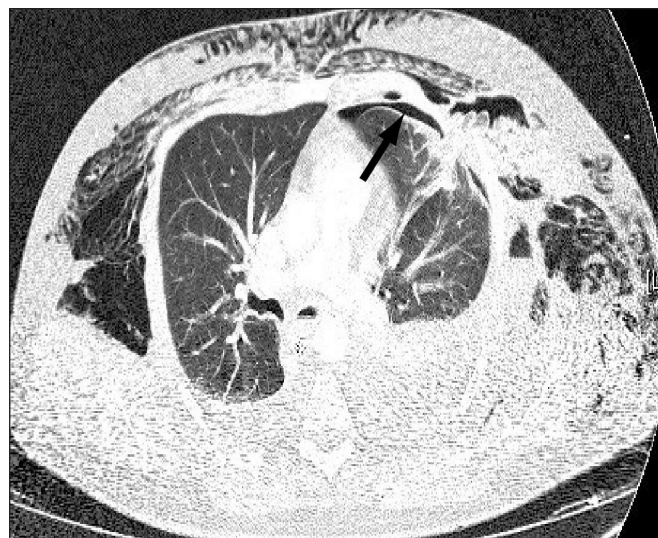


Fig. 2. Computed tomography scan showing associated pneumothorax (arrow).

received conservative management with insertion of a chest tube and ongoing monitoring. Follow-up CT 2 weeks later showed resolution of both the pneumothorax and the lung herniation. The patient died 1 week later after a second episode of massive variceal bleeding.

DISCUSSION

The rib fractures and thoracic trauma that our patient received during CPR caused the lung parenchyma to herniate through a rib fracture. This mechanism is similar to other forms of acquired lung hernias due to blunt trauma, resulting from multiple costal and sternal fractures; the associated costochondral separation opens a hernia window in the chest wall.² Anteriorly, the chest wall is weakest from the costochondral junction to the sternum, owing to an absence of external intercostal muscles. Thus, anterior lung herniation accounts for most acquired lung hernias, which are often caused by seat-belt injury.

According to the current literature on post-traumatic pulmonary herniation, the majority of patients remain asymptomatic. In this setting, a soft, reducible, bulging mass in the chest wall or neck may be noted that changes in size with the respiratory cycle, coughing or straining.³ Initially on chest radiography, lung parenchymal hernias may appear as loculated subcutaneous air pockets.⁴ However, in the majority of blunt trauma patients with hernias, CT is the preferred modality to identify the hernia, but in those who have respiratory symptoms, physicians must be acutely aware of herniation because of the possible complications. In CPR-induced lung herniation, patients may also be asymptomatic, but clinical suspicion should be high, especially if rib fractures are suspected or confirmed radiographically. Lung herniation should be considered whenever a patient has a bulging mass in the anterior thorax, intractable pain at the site of a potential fracture, ongoing dyspnea with no definite etiology, subcutaneous emphysema, suspicious (especially bloody) pleural effusions or pneumothorax after CPR.

Lung herniation after CPR remains rare, and has been described only twice before in the literature.^{5,6} A large case

series of 705 post-CPR autopsies conducted by Krischer and colleagues⁷ did not describe a single case of lung herniation, although it is not known how many lung herniations would have occurred if all 705 patients had survived resuscitation.

In asymptomatic patients, management may be conservative, with careful monitoring of the patient's respiratory function and follow-up imaging with serial CT until resolution. This will minimize the risk of further complications. Owing to the risk of incarceration and strangulation of herniated lung parenchyma, as well as the increased risk of pneumothorax with the use of mechanical ventilation with positive end-expiratory pressure, surgical intervention may be chosen. The decision to pursue surgical intervention or conservative observation in CPR-induced lung herniation is made on a case-by-case basis. Symptomatic patients with intractable pain, dyspnea, incarceration or ongoing effusion, for example, would merit surgical intervention because the risk of acute respiratory decompensation is high. In the past, this has been the approach for most traumatic pulmonary hernias. Larger hernias may require pericostal fixation of adjacent ribs with absorbable sutures and repair of the lacerated lung. Rarely, fascia lata grafts and muscle flaps may be used to bridge the defect.⁴

Competing interests: None declared.

References

1. Hoke RS, Chamberlain D. Skeletal chest injuries secondary to cardiopulmonary resuscitation. *Resuscitation* 2004;63:327-38.
2. Francois B, Desachy A, Cornu E, et al. Traumatic pulmonary hernia: surgical versus conservative management. *J Trauma* 1998;44:217-9.
3. Fiane AE, Nordsrand K. Intercostal pulmonary hernia after blunt thoracic injury. *Eur J Surg* 1993;159:379-81.
4. Allen GS, Fischer RP. Traumatic lung herniation. *Ann Thorac Surg* 1997;63:1455-6.
5. Batra AK. Lung herniation after CPR. *Crit Care Med* 1986;14:595-6.
6. Sprague LD, Ferrigni FJ. Images in clinical medicine. Lung herniation after cardiopulmonary resuscitation. *N Engl J Med* 2004;351:695.
7. Krischer JP, Fine EG, Davis JH, et al. Complications of cardiac resuscitation. *Chest* 1987;92:287-91.