

Surgical technique

Posterolateral approach for open reduction and internal fixation of trimalleolar ankle fractures

Max Talbot, MD;* Trent R. Steenblock, DPM;† Peter A. Cole, MD*‡

The standard indication for fixing a posterior malleolar fracture is a displaced fragment that involves more than 25%–35% of the articular surface of the distal tibia.^{1,2} A number of different surgical approaches to this fracture have been advocated.^{1–7}

Often, the posterior fragment reduces simultaneously when the lateral malleolus is reduced because of their respective attachments to the posteroinferior tibiofibular ligament (PITFL). This fragment, also known as a Volkmann's fragment, can then be fixed with lag screws inserted from anterior to posterior. This expected reduction is not likely if the ankle is not being fixed acutely because of the interposition of organized hematoma or callus. Further, it would seem that a supine approach to an ankle fracture with a posterior malleolus fragment fixed with screws placed anterior to posterior would be analogous to fixing a lateral tibial plateau fracture with screws from the medial side.

If direct exposure of the fragment is necessary, the posteromedial approach has been recommended.^{2,7} This allows fixation of the medial and posterior malleoli through the same incision. The limited visualization of the posterior malleolar fragment afforded by this exposure has led other authors to describe different techniques to facilitate anatomical reduction. One such approach is to use the same posteromedial incision and ac-

cess the posterior malleolus by incising the sheaths of the tibialis posterior and flexor digitorum longus tendons and retracting them anteriorly.³ A medial approach for a typically posterolateral fragment still would seem suboptimal. An extensile posteromedial approach with dislocation of the talus laterally and complete release of soft-tissue attachments to the posterior malleolus has also been described.¹ This seems overly aggressive and can compromise syndesmotic integrity. Other options include arthroscopically assisted reduction⁴ and the lateral transmalleolar approach.⁵ It is very difficult to get an anatomical reduction of the posterior malleolus fragment using a lateral transmalleolar approach, however, because the PITFL is attached to the unreduced fibula.

The purpose of this paper is to describe in detail a different method of approach and fixation that has proved very useful in the authors' experience: open reduction and internal fixation (ORIF) of trimalleolar ankle fractures using the posterolateral approach. The posterolateral approach has been described in the literature but has not received much attention.⁶ The rationale and nuances of the execution of this approach will be elaborated on here.

Technique

Surgery is performed in the prone posi-

tion with a bump under the ipsilateral hip. Alternatively, the patient may be placed in the lateral decubitus position if there is no medial malleolus fracture. If there is such a fracture, the prone approach must be used for simultaneous access to the medial side.

A posterolateral approach is performed.⁶ The longitudinal incision is placed just medial to the posterior border of the fibula (Fig. 1). We find that this gives good access to the Volkmann's fragment and optimal access to the lateral malleolus. The lesser saphenous vein and sural nerve are identified and protected. The sural nerve courses from medial to lateral and crosses the lateral border of the Achilles tendon on average 9.8 cm proximal to its insertion in the calcaneus.⁸ At a point 7 cm proximal to the tip of the lateral malleolus, the nerve is on average 26 mm posterior to the edge of the fibula.⁹ It gives rise to an average of 3 branches in the retromalleolar region, the lateral calcaneal nerves.⁹ The surgeon must be aware that the anatomy of the sural nerve is highly variable,^{8–10} and the best way to protect it and avoid nerve injury and neuromas is to perform meticulous blunt dissection in the subcutaneous tissue. Retracting the peroneal tendons medially gives access to the posterior aspect of the lateral malleolus. The fibular fracture is classically fixed with a lag screw and an antiglide plate, but the fixation construct may vary according to

From the *Department of Orthopaedic Surgery, University of Minnesota, Minneapolis, the †Department of Podiatry and the ‡Department of Orthopaedic Surgery, Regions Hospital, St. Paul, Minn.

Accepted for publication Mar. 23, 2005

Correspondence to: Dr. Peter A. Cole, Chief of Orthopaedic Trauma, Department of Orthopaedic Surgery, Regions Hospital, 640 Jackson St., St. Paul MN 55101; fax 651 254-1519; peter.a.cole@HealthPartners.com

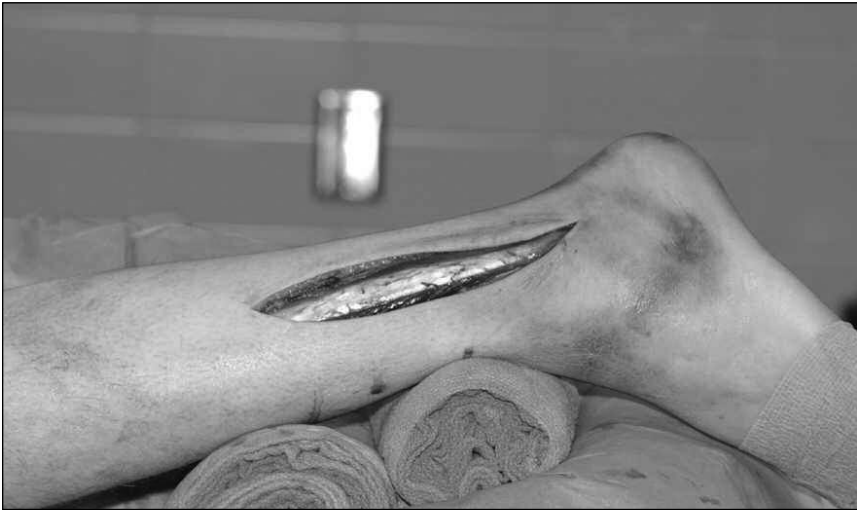

FIG. 1. The skin is incised, showing the peroneal tendons.



FIG. 2. View of the posterior fragment in the interval between the peroneal tendons and the flexor hallucis longus.

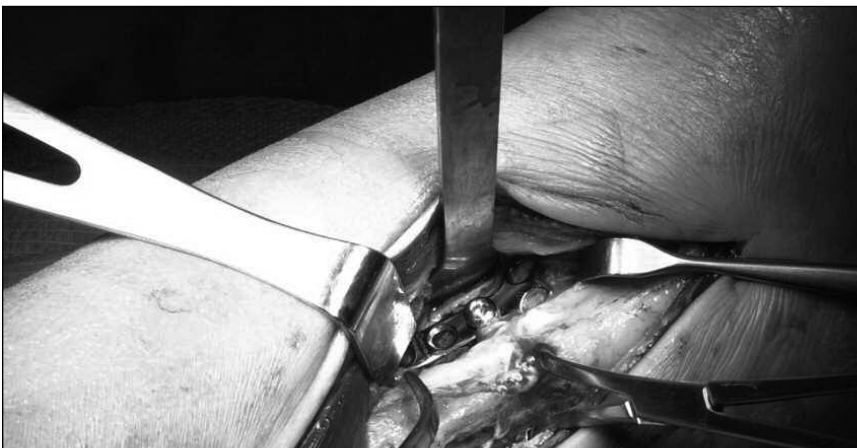


FIG. 3. In this case, the fibula and the posterior tibia are both approached by reclining the peroneal tendons medially.

fracture pattern or comminution. In more complex fracture patterns, stacked one-third tubular plates or a limited contact dynamic compression (LC-DC) plate can be used to provide additional stability. The one-third tubular plate is contoured by narrowing the corners at its distal end to fit closely over the posterior border of the distal fibula. This contour ensures that it will not impinge on the peroneal tendons.

A second interval is then exploited between the peroneal tendons and Achilles tendon more medially within the wound (Fig. 2). The flexor hallucis longus is lifted off the posterior tibia allowing access to the posterior malleolus. Care is taken to preserve the PITFL attachment to the fragment and the joint capsule, which means the fragment should be booked open from medial to lateral for joint inspection. Blood is supplied to the posterior tibia by the perimalleolar arterial ring from which fine arterial branches penetrate the bone 2.5–5 cm proximal to the joint line.¹¹ Care should be taken merely to clean and define the fracture edge, and not to devascularize the fragment. The fragment, depending on its size, is fixed with screws from the small or mini fragment set. A small buttress plate can also be used to supplement fixation. This is our preferred method of fixation. Alternatively, both the posterior and lateral malleolus can be accessed through the same intermuscular plane between the peroneal tendons and the posterior border of the fibula (Fig. 3).

Lastly, the medial malleolus can be addressed through a standard medial incision. Access to the medial side is slightly more challenging in the prone position, as compared with the supine position, because of the leg's propensity to rotate externally. The level of difficulty is further increased in patients with out-toeing, in which case it is helpful to have an assistant hold the lower limb in internal rotation. Fixation of the medial side is carried out classically with two 3.5 lag screws, but again may vary according to fracture pattern.

One of the challenges during execution of the surgery is obtaining an accurate lateral C-arm image of the ankle. This image requires internal rotation of the leg, which can be accomplished by rotating the leg by gripping the knee proximally or by rotating the bed 5°–10°. An image intensifier is used to assess fracture reduction and position of

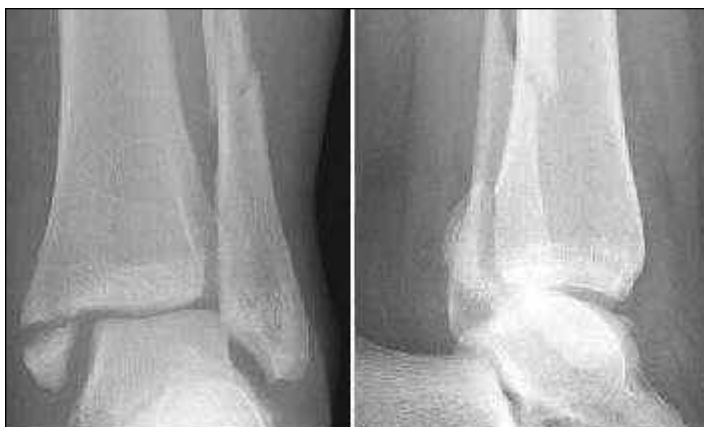

FIG. 4. Anteroposterior and lateral radiographs showing a displaced trimalleolar fracture.

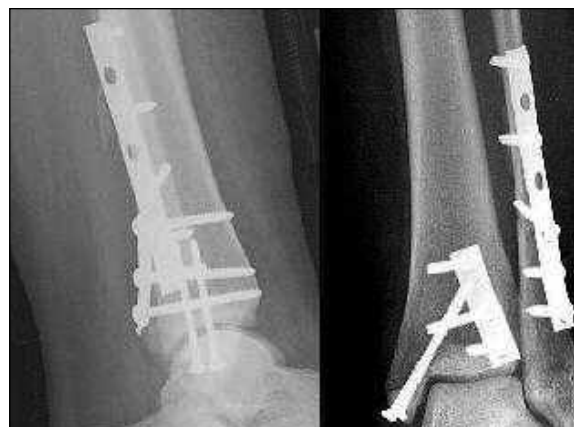

FIG. 5. Postoperative anteroposterior and lateral radiographs. An antiglide plate has been applied to the fibula. Lag screws and a buttress plate have been used to fix the posterior malleolus.

the implants, which the authors advocate. Alternatively, C-arm imaging can be omitted, and radiographs can be taken after fixation. Figure 4 and Figure 5 show typical preoperative and postoperative radiographs, respectively.

Discussion

There are few reports of this approach in the peer-reviewed literature. Miller reported on 5 cases of ORIF of the posterior malleolus using this exposure but gave scant details regarding patient outcomes.¹² Heim reported on 60 trimalleolar fractures treated surgically, 16 of which were treated through this approach. He found it especially useful for patients with smaller, posterior fragments.¹³ Both these authors gave few details on the technical aspects of this approach.

In our experience, we have found that a posterolateral approach has several advantages. The main advantage is that it allows a direct inspection and reduction of the posterior fragment. The approach allows one to address the fragment in a manner consistent with the classic fracture pattern that is parallel to the transmalleolar axis and, thus, posterolateral.¹⁴ Anatomical reduction of articular surfaces is a basic principle in fracture surgery, and this approach certainly promotes that goal. This was nicely shown in a study by Huber et al.¹⁵ They found that anatomical reduction of the posterior malleolus was more frequent with direct reduction (83% of cases) when compared with the standard indirect reduction and anteroposterior screws (27% of cases). In the

case of delayed surgery, the fracture can be cleaned out directly, removing interposed callus or periosteum, once again promoting an anatomical articular reduction. And, lastly, the direct visualization allows for the joint to be inspected for osteochondral fragments, talar chondral damage or impaction injury.

There are other advantages as well. In the case of fracture dislocations, gravity is an intraoperative aid rather than a deforming force during the procedure. With this exposure, the surgeon can choose to supplement fixation of the posterior malleolus with a buttress plate, also a basic fixation principle in a weight-bearing joint that will experience axial load or shearing forces during weight bearing. We also believe that fixation of even small posterior malleolus fragments can facilitate rehabilitation by creating a more stable construct. This might prevent subluxation of the talus and stabilize the syndesmosis, conceivably making early range of motion easier on the patient. This is consistent with modern rehabilitation principles. This is in contrast to early studies that showed no benefit to fixation of even large posterior malleolus fragments.¹⁶ In this study, all patients were immobilized for 6–12 weeks after surgery.

In addition, this is the exposure of choice for the use of an antiglide plate for fibular fixation. Such a posterolateral fibular construct has been shown in biomechanical studies to be superior to the more commonly used lateral plate.¹⁷ Soft-tissue coverage for the plate is also enhanced in the posterior fibular position. However, these benefits from the

antiglide plate were not clear in a recent clinical study.¹⁸

It is true that the prone position can make ORIF of the medial malleolus more challenging, but the medial malleolus is generally the easier of the malleoli to reduce and fix. This is the trade-off for having direct access and more fixation options for the posterior malleolus. There are other drawbacks to this approach. It is not extensile distally. Furthermore, in cases with associated forefoot or talus fractures or anterior syndesmosis injuries, moving the patient to a supine position will be necessary as these injuries cannot be addressed through this incision or in the prone position.

In summary, we believe that the posterolateral approach to the ankle provides the optimal exposure for fixation of trimalleolar fractures. Although it has been described in the past, there are few technical details in the published literature regarding this approach that can guide surgeons unfamiliar with it. Surgeons could benefit from using this underappreciated exposure.

Competing interests: None declared for Drs. Steenblock and Cole. Dr. Talbot has received speaker fees from Synthes and an educational grant to attend an AO/ASIF Association for the Study of Internal Fixation course.

References

1. Grantham SA. Trimalleolar ankle fractures and open ankle fractures. *Instr Course Lect* 1990;39:105-11.
2. Carr J. Malleolar fractures and soft tissue

Technique chirurgicale

- injuries of the ankle. In: Browner B, Jupiter J, Levine A, Trafton P, editors. *Skeletal trauma: basic science, management, and reconstruction*. Vol 2. 3rd ed. Philadelphia: Elsevier Science; 2003. p. 2307-74.
- Mizel MS, Temple HT. Technique tip: revisit to a surgical approach to allow direct fixation of fractures of the posterior and medial malleolus. *Foot Ankle Int* 2004;25:440-2.
 - Holt ES. Arthroscopic visualization of the tibial plafond during posterior malleolar fracture fixation. *Foot Ankle Int* 1994;15:206-8.
 - Warner WC, Farber LA. Trimalleolar fractures. *South Med J* 1965;58:1292-5.
 - Hoppenfeld S, deBoer P. *Surgical exposures in orthopaedics: the anatomic approach*. 2nd ed. Philadelphia: Lippincott, Williams, & Wilkins; 1994.
 - Marsh JL, Saltzman C. Ankle fractures. In: Bucholz R, Heckman J, editors. *Rockwood and Green's fractures in adults*. Vol 2. 5th ed. Philadelphia: Lippincott, Williams, & Wilkins; 2001. p. 2001-90.
 - Webb J, Moorjani N, Radford M. Anatomy of the sural nerve and its relation to the Achilles tendon. *Foot Ankle Int* 2000;21:475-7.
 - Lawrence SJ, Botte MJ. The sural nerve in the foot and ankle: an anatomic study with clinical and surgical implications. *Foot Ankle Int* 1994;15(9):490-4.
 - Huene DB, Bunnell WP. Operative anatomy of nerve encountered in the lateral approach to the distal part of the fibula. *J Bone Joint Surg Am* 1995;77:1021-4.
 - Giebel GD, Meyer C, Koebke J, Giebel G. The arterial supply of the ankle joint and its importance for the operative fracture treatment. *Surg Radiol Anat* 1997;19:231-5.
 - Miller AJ. Posterior malleolar fractures. *J Bone Joint Surg Br* 1974;56B:508-12.
 - Heim UF. Trimalleolar fractures: late results after fixation of the posterior fragment. *Orthopedics* 1989;12:1053-9.
 - Macko VW, Matthews LS, Zwirkoski P, Goldstein SA. The joint-contact area of the ankle. The contribution of the posterior malleolus. *J Bone Joint Surg Am* 1991;73:347-51.
 - Huber M, Stutz P, Gerber C. Open reduction and internal fixation of the posterior malleolus with a posterior antiglide plate using a postero-lateral approach: a preliminary report. *J Foot Ankle Surg* 1996;2:95.
 - Harper MC, Hardin G. Posterior malleolar fractures of the ankle associated with external rotation-abduction injuries. Results with and without internal fixation. *J Bone Joint Surg Am* 1988;70:1348-56.
 - Schaffer JJ, Manoli A II. The antiglide plate for distal fibular fixation. A biomechanical comparison with fixation with a lateral plate. *J Bone Joint Surg Am* 1987;69:596-604.
 - Lamontagne J, Blachut PA, Broekhuysen HM, O'Brien PJ, Meek RN. Surgical treatment of a displaced lateral malleolus fracture: the antiglide technique versus lateral plate fixation. *J Orthop Trauma* 2002;16:498-502.

CMA Careers

Where

can I search physician job listings?

CMA Careers is the largest resource in Canada, for physician job listings in print and online. The entry point for online recruitment listings of *CMAJ* and other specialty journals is www.cmacareers.ca.

Whether you want a career move that takes you across Canada or a few doors down, make CMA Careers your resource.

ASSOCIATION
MÉDICALE
CANADIENNE



CANADIAN
MEDICAL
ASSOCIATION

Visit careers at cma.ca today!

710 JPN23