

Soft-tissue images. Appendiceal inguinal hernia

A 65-year-old man underwent barium enema examination for investigation of rectal bleeding. Sigmoid diverticular disease was diagnosed, but in addition the vermiform appendix was noted to be lying within an asymptomatic right inguinal hernia (Fig. 1). In addition to appendiceal diverticula, multiple fecaliths were evident within the lumen of the appendix. The patient was therefore at risk for the development of appendicitis in the hernial sac (Amyand's hernia^{1*}). He underwent simultaneous hernia repair and appendectomy (Fig. 2) with broad-spectrum antibiotic prophylaxis. His postoperative course was smooth, without wound complications or hernia recurrence.

Only rarely is the diagnosis of an appendiceal inguinal hernia made preoperatively.² Even with perforation, appendicitis in this unusual position is difficult to diagnose.³ If the vermiform appendix is encountered

unexpectedly in a hernial sac during elective herniorrhaphy, the risk of appendicitis (e.g., the presence of fecaliths) should be weighed against the risks of wound or mesh infection, and of hernia recurrence,⁴ when deciding on a concomitant appendectomy.⁵

References

1. Amyand C. Of an inguinal rupture, with a pin in the appendix caeci incrusted with stone; and some observations on wounds in the guts. *Phil Trans R Soc Lond* 1736; 39:329-42.
2. Akfirat M, Kazez A, Serhatlioglu S. Preoperative sonographic diagnosis of sliding appendiceal inguinal hernia. *J Clin Ultrasound* 1999;27:156-8.
3. Lyass S, Kim A, Bauer J. Perforated appendicitis within an inguinal hernia: case report and review of the literature. *Am J Gastroenterol* 1997;92:700-2.
4. Rose E, Santulli TV. Sliding appendiceal inguinal hernia. *Surg Gynecol Obstet* 1978; 146:626-7.
5. Hutchinson R. Amyand's hernia. *J R Soc Med* 1993;86:104-5.

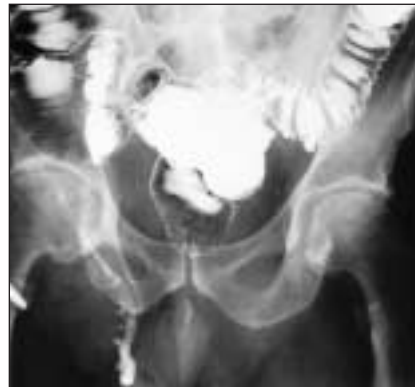

FIG. 1. Barium enema examination showing the vermiform appendix in a right inguinal hernia.

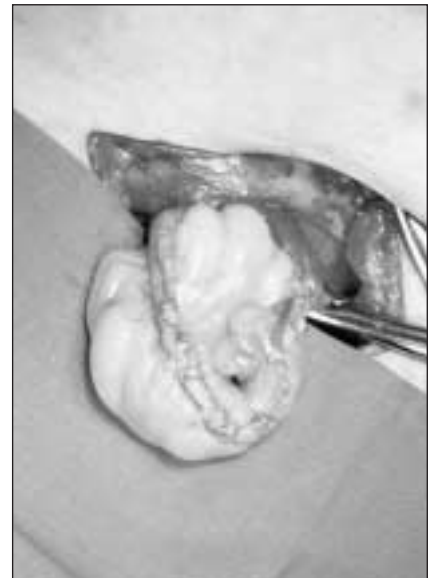


FIG. 2. Operative view showing the vermiform appendix in a hernial sac.

*Claudius Amyand (1681-1740), Sergeant-Surgeon to King George II and Principal Surgeon to St. George's Hospital, London, UK. In 1735 he performed the first appendectomy for a discharging fecal fistula due to a perforated appendix in an inguinal hernia.¹

Section Editors: David P. Girvan, MD, and Nis Schmidt, MD

Submitted by Kirsten S. Hindle, MB BS, Department of Surgery, Mayday Hospital, Croydon, UK, and Andy Huang, MB ChB, Department of Surgery, The Royal Croydon Hospital, Croydon, UK.

Submissions to *Surgical Images*, soft-tissue section, should be sent to Dr. David P. Girvan, Victoria Hospital Corporation, PO Box 5375, Station B, London ON N6A 5A5 or to Dr. Nis Schmidt, Department of Surgery, St. Paul's Hospital, 1081 Burrard St., Vancouver BC V6Z 1Y6.

Correspondence to: Mr. Andy Huang, 40 York Terrace E., Regent's Park, London NW1 4PT, UK; fax 44 7889 320-024; andyhuang@talk21.com