

Musculoskeletal case 19. Presentation

A 33-year-old man presented with a 2-year history of intermittent, progressive, aching pain of his right knee. He had also lately noted some restriction of movement. On examination there was mild tenderness over the medial

joint line, with minimal swelling. Plain radiographs were initially obtained to evaluate the cause of his pain (Figs. 1 and 2). On the basis of the plain radiographic findings, magnetic resonance imaging was performed. Fig. 3 is a representative

sagittal T_2 -weighted gradient echo image and Fig. 4 is a representative transaxial T_2 -weighted image. From these imaging characteristics, what is your diagnosis?

For the diagnosis and discussion see [page 468](#).

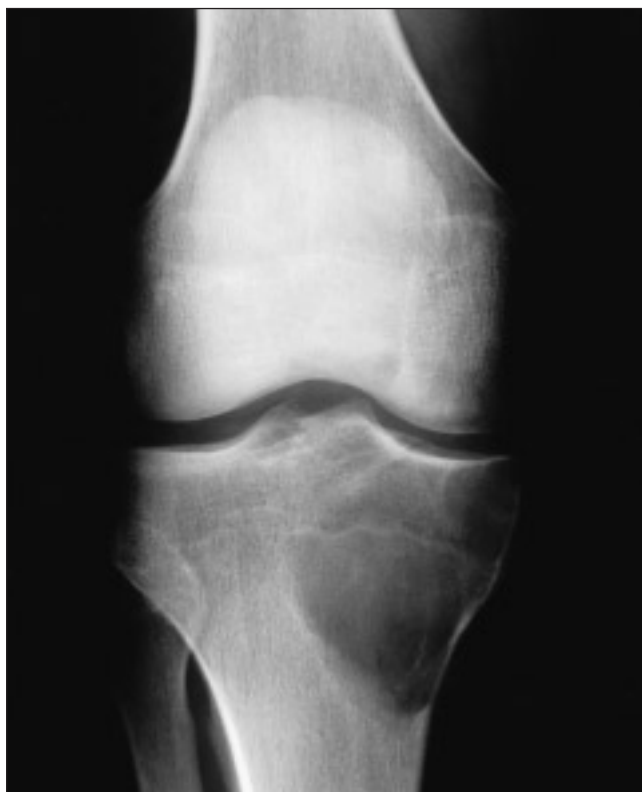

FIG. 1.

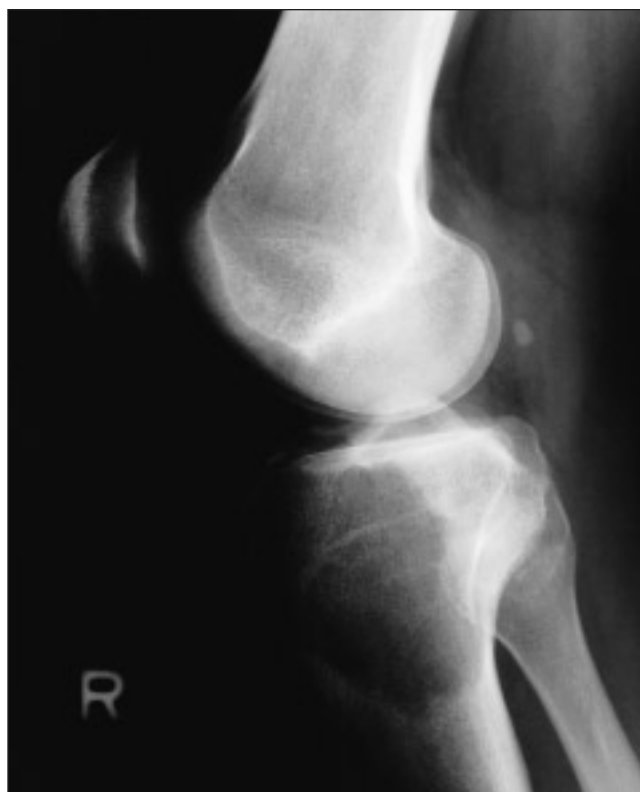

FIG. 2.

Section Editor: Peter L. Munk, MD

Submitted by William C. Torreggiani, MB, Khalid Al-Ismail, MB, Fahad Al-Sheikh, MB, Ciaran Keogh, MB, and Peter L. Munk, MD, Department of Radiology, Vancouver General Hospital, Vancouver, BC

Inquiries about this section should be directed to Dr. Peter L. Munk, Professor, Department of Radiology, Vancouver General Hospital and Health Sciences Centre, 855 West 12th Ave., Vancouver BC V5Z 1M9.

© 2001 Canadian Medical Association

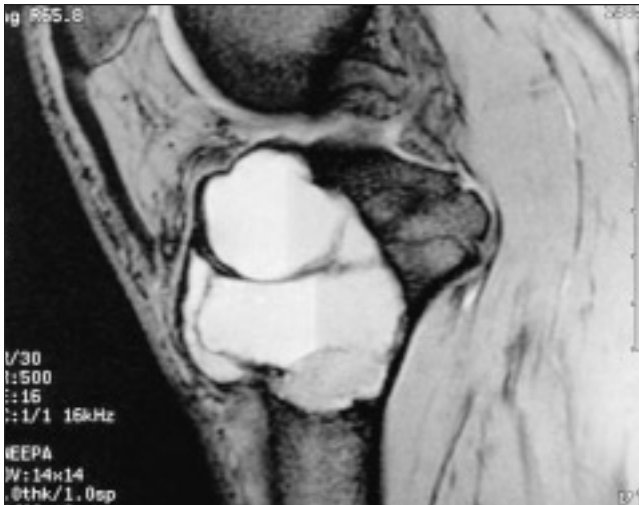


FIG. 3.

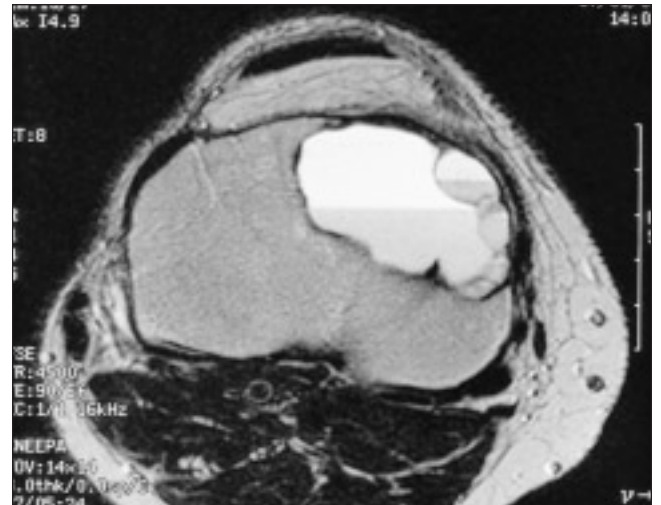


FIG. 4.

**NOTICE OF CHANGE OF ADDRESS
AVIS DE CHANGEMENT D'ADRESSE**

To ensure that you continue to receive the *Canadian Journal of Surgery* without interruption, please fill in and mail this form before you move.

Avant de déménager, assurez-vous de recevoir sans interruption le *Journal canadien de chirurgie* en complétant et en expédiant le formulaire suivant.

Please print / En lettres moulées, svp

Name / Nom

Old address / Ancienne adresse

New address / Nouvelle adresse

Date effective / Date en vigueur

Subscribers please mail to: Member Service Centre, Canadian Medical Association, 1867 Alta Vista Dr., Ottawa ON K1G 3Y6.

Abonnés, veuillez expédier au : Centre des services aux membres, Association médicale canadienne, 1867, prom Alta Vista, Ottawa ON K1G 3Y6.

US address changes / Envoyer les changements d'adresse américaine à : International Media Services (IMS) of New York, 100 Walnut St., #3, PO Box 1518, Champlain NY 12919-1518.