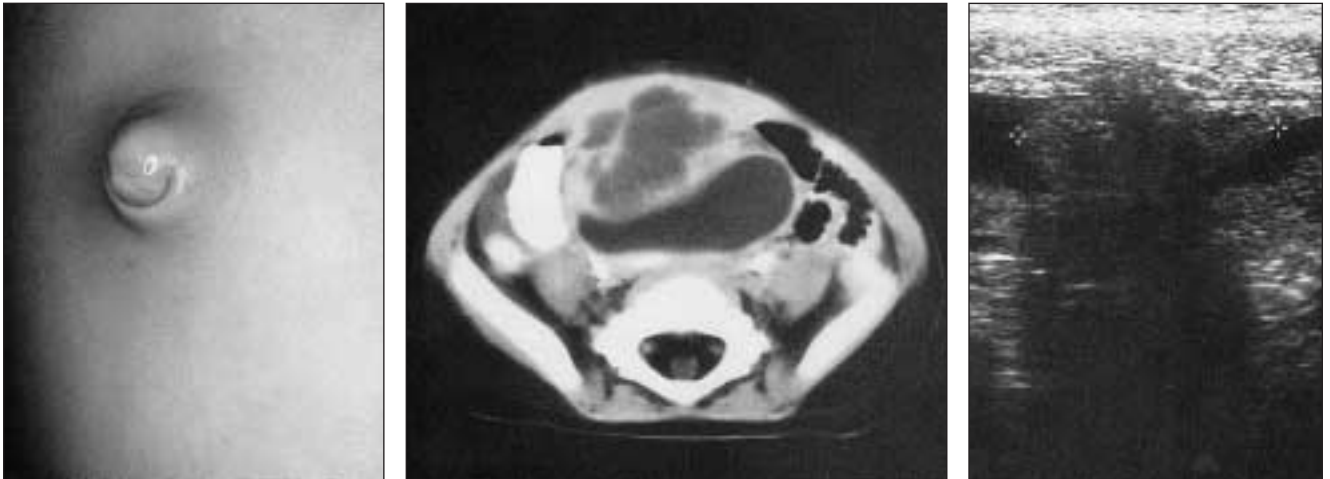


**Category 15, Item 16**

A 15-month-old female has umbilical firmness and abdominal pain. The child has had a swollen, tender umbilicus for about seven days and has not been acting normally. Prior to this she was totally healthy with no medical problems. On physical examination, vital signs are normal. WBC count is 21,500/cu mm; all other laboratory tests are normal. The appearance of the umbilicus, ultrasonography of the area, and an abdominal computed tomographic (CT) scan are shown.



The most likely diagnosis is

- (A) incarcerated umbilical hernia
- (B) infected urachal cyst
- (C) infected omphalomesenteric duct
- (D) necrotizing enterocolitis
- (E) Meckel's diverticulum

For the incomplete statement above, select the answer that is best out of the 5 given.

For the critique of item 16, see [page 139](#).

(Reproduced by permission from *SESAP No. 10 1999–2001 Syllabus* Volume 2. For enrolment in the Surgical Education and Self-Assessment Program, please apply to the American College of Surgeons, 633 North St. Clair St., Chicago IL 60611, USA.)