

## UNICONDYLAR KNEE ARTHROPLASTY: A CEMENTLESS PERSPECTIVE

Michael E. Forsythe, BSc, MD;\* Roy E. Englund, MD; Ross K. Leighton, MD

**OBJECTIVE:** To compare the results of cementless unicondylar knee arthroplasty (UKA) with those already reported in a similar study on cemented UKA.

**DESIGN:** A case-series cross-sectional study.

**SETTING:** The Queen Elizabeth II Health Sciences Centre, Dalhousie University, Halifax.

**PATIENTS:** Fifty-one patients who underwent a total of 57 UKAs between May 1989 and May 1997. Inclusion criteria were osteoarthritis involving the predominantly the medial compartment of the knee, relative sparing of the other compartments, less than 15° of varus, minimal knee instability, and attendance at the postoperative clinical visit.

**INTERVENTION:** Cementless UKA.

**MAIN OUTCOME MEASURES:** Clinical parameters that included pain, range of motion and the Knee Society Clinical Knee Score. Roentgenographic parameters that included  $\alpha$ ,  $\beta$ ,  $\gamma$  and  $\sigma$  angles and the presence of periprosthetic radiolucency or loose beads.

**RESULTS:** Age, weight, gender and follow-up interval did not significantly affect the clinical results in terms of pain, range of motion or knee score. Knees with more than 1 mm of radiolucency had significantly lower knee scores than those with no radiolucency. Knees that radiologically had loose beads also had significantly lower knee scores. The clinical outcomes of cementless UKA were comparable to those already reported on cemented UKA. Cementless femurs had less radiolucency than the cemented femurs, whereas cementless tibias had more radiolucency than their cemented counterparts.

**CONCLUSIONS:** Cementless UKA seems to be as efficacious as cemented UKA. However, there is some concern about the amount of radiolucency in the cementless tibial components. A randomized clinical trial comparing both cementless and cemented tibial components with a cementless femur (hybrid knee) is needed to further assess this controversial issue in UKA.

**OBJECTIF :** Comparer les résultats de l'arthroplastie unicondylaire du genou (AUG) sans ciment à ceux qui ont déjà fait l'objet de rapports dans le contexte d'une étude semblable sur l'AUG cimentée.

**CONCEPTION :** Étude transversale d'une série de cas.

**CONTEXTE :** Le Centre des sciences de la santé Queen Elizabeth II, Université Dalhousie, Halifax.

**PATIENTS :** Cinquante-et-un patients qui ont subi au total 57 AUG entre mai 1989 et mai 1997. Les critères d'inclusion étaient l'arthrose touchant surtout le compartiment médial du genou, épargnant relativement les autres compartiments, varus de moins de 15°, instabilité minimale du genou et participation à une visite clinique postopératoire.

**INTERVENTION :** AUG sans ciment.

**PRINCIPALES MESURES DE RÉSULTATS :** Paramètres cliniques incluant la douleur, l'amplitude du mouvement et le score clinique proposé par la Knee Society. Paramètres radiographiques incluant les angles  $\alpha$ ,  $\beta$ ,  $\gamma$  et  $\sigma$  et la présence d'une perméabilité aux rayons X dans la région de la prothèse ou de grains en liberté.

*From the Department of Surgery, Faculty of Medicine, Dalhousie University, Halifax, NS*

*Presented at the meeting of the Atlantic Provinces Orthopaedic Society, Halifax, NS, September 1997.*

*\*Orthopaedic Resident, Faculty of Medicine, Dalhousie University, Halifax; winner 1999 MacLean–Mueller Prize*

*Accepted for publication Oct. 2, 2000.*

*Correspondence to: Dr. Ross K. Leighton, Rm. 4873, New Halifax Infirmary Site, Queen Elizabeth II Health Sciences Centre, 1796 Summer St., Halifax NS B3H 3A7; reprint requests to: fax 902 473-4490.*

*© 2000 Canadian Medical Association*

RÉSULTATS : L'âge, le poids, le sexe et l'intervalle du suivi n'ont pas eu d'effet important sur les résultats cliniques en ce qui concerne la douleur, l'amplitude du mouvement ou le score du genou. Les genoux qui avaient une perméabilité aux rayons X de plus de 1 mm présentaient des scores beaucoup moins élevés que ceux qui n'avaient aucune perméabilité. Les genoux qui contenaient des grains en liberté avaient des scores beaucoup moins élevés. Les résultats cliniques de l'AUG sans ciment étaient comparables à ceux qu'on avait déjà signalés pour les AUG cimentées. Les fémurs sans ciment étaient moins perméables aux rayons X que les fémurs cimentés, tandis que les tibias sans ciment étaient plus perméables que les tibias correspondants cimentés.

CONCLUSIONS : L'AUG sans ciment semble aussi efficace que l'AUG cimentée. L'importance de la perméabilité aux rayons X dans les pièces tibiales sans ciment préoccupe toutefois un peu. Une étude clinique randomisée comparant les pièces tibiales avec et sans ciment à un fémur sans ciment (genou hybride) s'impose pour évaluer plus à fond cet aspect controversé de l'AUG.

The proper treatment of primary unicompartamental osteoarthritis of the knee is controversial. Some of the treatment options available to the orthopedic surgeon include arthroscopic or open débridement, McKeever hemiarthroplasty, high tibial osteotomy, total knee arthroplasty (TKA), unicompartmental knee arthroplasty (UKA) and arthrodesis.<sup>1</sup> Arthroscopic débridement can provide some short-term pain relief in patients with mild arthritic changes (grades I or II [arthroscopic and radiologic classifications]), but long-term results are disappointing, and another definitive procedure is usually necessary.<sup>2</sup> McKeever hemiarthroplasty, with or without osteotomy, has given temporary relief to some patients who are not candidates for TKA or UKA, but again this is only temporary.<sup>3</sup>

High tibial osteotomy (HTO) has excellent short-term results but deterioration follows regardless of the alignment achieved at the time of osteotomy assessment.<sup>4,5</sup> The initial rehabilitation from this procedure is much more extensive than from the other surgical interventions. In a patient under 55 years of age who weighs over 90.7 kg and who presents with moderate arthritic changes (grade II), less than 15° of genu varum mechanical deformity, and at least 90° of flexion, HTO is a reasonable option, providing good pain relief. Revisions after HTO have also shown a greater clinical success rate than those after UKA or TKA.<sup>6</sup> On the other hand, many studies compar-

ing medial UKA and HTO have proven that UKA provides more consistent pain relief than HTO.<sup>7,8</sup>

For patients with end-stage osteoarthritis, there are 2 remaining surgical options: TKA or UKA. Although long-term results of TKA are superior,<sup>9-12</sup> UKA has many theoretical advantages over TKA that make it an attractive option for the properly selected patient. These advantages include decreased postoperative morbidity, minimal loss of bone stock, preservation of both cruciate ligaments, complete preservation of the patellofemoral articulation and increased range of motion.<sup>1,13</sup> Preservation of both cruciate ligaments may increase the stability within the knee; however, it has not been shown to improve proprioception.<sup>14</sup>

Although UKA and TKA were developed at the same time, UKA has not gained the widespread acceptance that TKA has. The earliest reports on UKA by Insall and Aglietti,<sup>15</sup> Insall and Walker<sup>16</sup> and Laskin<sup>17</sup> suggested that the procedure had a high failure rate and should not be considered except in some cases of lateral compartment disease. Recently, more favourable early and long-term results have been achieved by Marmor,<sup>18,19</sup> the Brigham Group,<sup>1,20,21</sup> and others.<sup>22,23</sup>

The decision to implant a unicompartmental knee is a difficult one because orthopedic surgeons worldwide achieve excellent results with TKA in terms of pain relief, range of motion and mechanical alignment. Many of

the advantages of UKA over TKA have been eliminated by recent technological advances in the latter procedure. Most surgeons who enjoy success with UKA have strict patient selection criteria and routinely perform UKA. Patient selection involves not only careful analysis of the clinical and radiologic features of each patient but also a thorough intraoperative assessment of the degree of arthritis.<sup>24</sup>

In their 1989 review, Kozinn and Scott<sup>25</sup> determined that the best candidates for UKA are those who weigh less than 82 kg, are older than 60 years, have a low level of activity and minimal pain at rest. They should also have close to 90° of flexion, less than 5° of flexion contracture, and less than 15° of angular deformity (range from 10° of varus to 15° of valgus) that can be passively corrected with removal of osteophytes.

There are several absolute contraindications to UKA including tricompartmental disease, inflammatory arthropathies, cruciate insufficiency, excessive deformity or bone loss. Although tricompartmental disease is an absolute contraindication, small cartilaginous erosions in the opposite compartment and chondromalacia patellae are only relative contraindications, depending on the patient's age and activity level.

Corpe and Engh<sup>26</sup> have quantitated the amount of cartilage wear found intraoperatively in the uninvolved compartments that still allows for a good outcome for unicompartmental replacement in the involved compartment. Others

state that UKA is indicated not only in elderly sedentary patients but also in the those aged 50 to 60 years who are relatively active, because bone stock is preserved for a possible revision to TKA.<sup>7</sup> In particular, results of the use of cementless unicondylar knee components in this younger age group may be more encouraging than the results obtained from the use of cemented components.

There are many long-term follow-up studies on cemented unicondylar knee components, but there is limited information on cementless components.<sup>27</sup> The purpose of this paper is to present follow-up results after cementless UKA using current, standardized, clinical and radiologic parameters.<sup>28,29</sup> We then attempted to compare our results with those in a similarly designed study (1989) as a historical control from a different centre on different cemented components.

**METHODS**

**Patient selection**

From May 1989 to May 1997, 65 patients underwent surgery for unicompartmental replacement of the medial compartment of the knee at the Queen Elizabeth II Health Sciences Centre in Halifax. Seven patients had bilateral procedures, giving a total of 72 medial compartment replacements. Contact was attempted with all patients for review; however, 7 (11%) patients were lost to follow-up because of the cost and inconvenience of travelling to and from Halifax. Six of these 7 patients had no knee pain or problems when interviewed on the telephone. One of the 7 patients reported moderate pain that was exacerbated with exercise, but there was no rest pain. Seven (11%) patients were dead at the time of follow-up. Telephone inquiry with family members revealed that all the deaths were unrelated to knee problems.

Thus, our study group consisted of 51 patients who underwent a total of 57 UKAs. The average patient age at the time of surgery was 68.3 years (range from 46.0 to 82.5 years). Mean follow-up was 40.2 months (range, from 12 to 96 months). The mean weight of the patients was 84 kg (range from 56 to 120 kg). No patients were seen preoperatively by the study team but were deemed appropriate candidates by only 1 of the coauthors (R.E.E.). The clinical indications for UKA were similar to those outlined by Kozinn and Scott.<sup>25</sup> They were osteoarthritis confined primarily to the medial or lateral compartment of the knee but not both, less than 15° of varus, and a diagnosis of degenerative arthritis. Universal contraindications were evidence of moderate bi- or tri-compartmental disease both clinically and radiographically, greater than 15° of varus, an unstable joint with or without cruciate disease, inflammatory arthritis such as rheumatoid arthritis and recent infection. All 65 patients had a preoperative diagnosis of degenerative arthritis of either the medial or lateral compartment with relative spar-

ing of the other compartments. The diagnosis was confirmed radiographically and intraoperatively.

**Surgical technique**

A Whiteside Ortholoc unicondylar knee prosthesis (Wright Medical, Mississauga, Ont.) (Fig. 1) was implanted in all patients. All tibial components were metal-backed cobalt chrome and were at least 10 mm thick (2 mm metal plus 8 mm polyethylene). All of the components were a cementless, press-fit system. The technique is similar to that of TKA, including the approach, the preparation of bone surfaces and the seating of the components.

The approach is a standard anterior longitudinal midline incision followed by a medial parapatellar capsulotomy. The patella is then turned laterally, and the patella and the medial and lateral surfaces of the knee are inspected for any arthritic changes. If a unicompartmental prosthesis is selected, then medial meniscectomy and partial synovectomy are performed.

The femoral preparation begins with the placement of the intra-

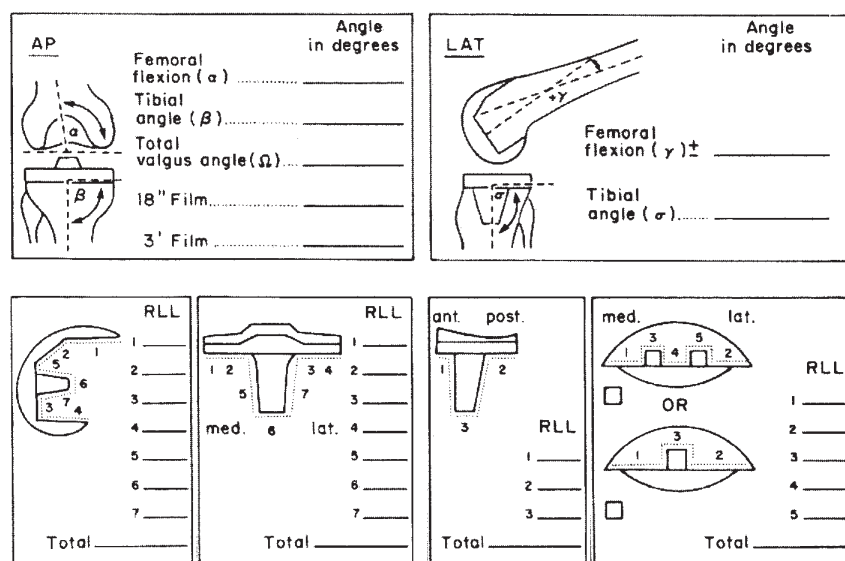


FIG. 1. The Knee Society total knee arthroplasty roentgenographic assessment: Top:  $\alpha$ ,  $\beta$ ,  $\gamma$  and  $\sigma$  angles. Bottom: radiolucent zones in total knee prostheses. AP = anteroposterior, RLL = radiographic lucent lines.

medullary rod and attached rotational alignment rod in the femoral canal. The femur and tibia are aligned, and the femoral cutting jig is attached to the intramedullary rod with the knee in the flexed position. A 7° cutting jig is used for women and 5° for men. Cut sizes are 6 mm for small, 7 mm for medium or large and 8 mm for extra large, but this depends on the amount of cartilage destruction and bone loss. The femoral surface is planed, and all osteophytes are removed with rongeurs. The posterior and bevel cutting guide is secured into place and these cuts are made with an oscillating saw. Care is taken to avoid the deep medial collateral ligament and anterior cruciate ligament fibres.

The tibial preparation also begins with the insertion of an intramedullary rod until the fins are embedded in the proximal tibia. The tibial cutting jig is applied and the tibial feeler is used to determine the deepest portion the involved tibial articular surface. If there is significant deformity in the involved surface, the uninvolved surface is used as a reference point. The tibial cut is then made so that 1 to 2 mm of bone is removed from the deepest portion of the involved surface, usually about an 8-mm cut. A 3° posterior jig is used, but if the posterior cut is excessively thin, then a 6° sloped jig can be used. The tibial trial that fits the best with less than 1 mm overhang is chosen and placed. A trial tibial tray is chosen that is 2 mm thicker than the tibial cut, with a minimum thickness of 10 mm to avoid impingement of the femur on the tibial spines. The femoral trial with the best fit is chosen, avoiding too much anterior overhang. Thicker tibial trays are used to correct varus and valgus deformity, and ligaments are manipulated to correct flexion contracture. The final femoral preparation is performed using a V-fin punch and a one-eighth inch drill bit for the peripheral pegs.

The tourniquet is deflated and all bleeding is controlled with electrocautery. The tourniquet is reinflated and the tibial component is inserted. The posterior screw is drilled at a 22° angle, while the anterior and middle screws are drilled to the nearest cortex at an angle of 10°. All holes are tapped, and titanium alloy screws of appropriate length are inserted. The cobalt chrome femoral component is placed and seated with the femoral seating instrument, followed by the polyethylene.

Student's *t*-test was used to analyse the differences between patients under and over the age of 60 years. A 1-way analysis of variance (ANOVA) was used to analyse the differences in the length of follow-up. A value of less than 0.05 was considered significant.

#### Clinical evaluation

The patients' clinical outcomes were evaluated using The Knee Society clinical rating system.<sup>28</sup> Scores were based on a maximum possible 100 points: 50 for pain control, 25 for stability and 25 for range of motion. Deductions were made for flexion contractures, extension lags and alignment variations. A functional score with 100 possible points was also given: 50 for walking distance on the level and 50 for walking stairs. Deductions were made for the use of canes, crutches or walkers, with a maximum possible score of 100 points.

The average pain score for our knees was 44.1 points out of a possible 50 points. The average range of motion was 103.2°. The average overall knee score was 88.0 points out of a possible 100 points. The average overall function score was 75.8 points.

#### Radiologic evaluation

Roentgenographic examination and evaluation were performed using The Knee Society total knee arthro-

plasty roentgenographic evaluation and scoring system.<sup>29</sup> This consisted of measuring the standard total knee angles ( $\alpha$ ,  $\beta$ ,  $\gamma$  and  $\sigma$ ) (Fig. 2) to ensure proper placement of the prosthesis in the knee joint, and then calculating the amount of periprosthetic radiolucency in millimetres (Fig. 2).



FIG. 2. Cementless unicondylar knee prosthesis (Whiteside Ortholoc II—Wright Medical Inc.).

## RESULTS

#### Clinical findings

Using Student's *t*-test, we found no significant difference between patients under 60 years of age compared with those over 60 years of age in terms of pain ( $p = 0.17$ ), range of movement ( $p = 0.32$ ) or knee score ( $p = 0.11$ ) (Table I). There was no significant difference between patients who weighed less than or equal to 90 kg and those who weighed more than 90 kg, with respect to pain ( $p = 0.20$ ), range of movement ( $p = 0.23$ ) or knee score ( $p = 0.22$ ) (Table II). There was no significant difference between women and men with respect to pain ( $p = 0.33$ ), range of movement ( $p = 0.41$ ) or knee score ( $p = 0.17$ ) (Table III). Using 1-way ANOVA, the length of follow-up at less than 2 years, from 2 to 5 years, or

longer than 5 years did not significantly alter knee outcomes in terms of pain ( $p = 0.09$ ), range of movement ( $p = 0.62$ ) or knee score ( $p = 0.17$ ) (Table IV).

Radiologic findings

The average  $\alpha$ ,  $\beta$ ,  $\gamma$  and  $\sigma$  angles were respectively  $93^\circ$ ,  $87.5^\circ$ ,  $1.8^\circ$  and  $83.9^\circ$ . The first 3 average angles were acceptable within the normal limits of  $95^\circ$ ,  $90^\circ$  and  $0^\circ$  respectively. However, the  $\sigma$  angle was lower than the normal value of  $87^\circ$ . On the lateral view, the tibial components that had  $\sigma$  angles less than  $85^\circ$  (posterior slope) were associated with radiolucency in the anterior portion of the tibial component (zone 1) on the lateral view.

To establish whether radiolucencies correlated with poor clinical outcome, we compared knee scores in those knees with 0 mm, 1 mm and greater than 1 mm of radiolucency. Using 1-way ANOVA, the knee scores in the above 3 categories were significantly different ( $p = 0.03$ ) (Table V). Using Fisher's protected least significant difference test, we found that only those knees with no radiolucency and those with greater than 1 mm of radiolucency had significantly different knee scores. Of the 57 knees, 31 (54.4%) had at least 1 mm of radiolucency.

Complications

Five (9%) knees in our study had evidence of loose beads within the knee joint. Of these patients, 2 had 5 mm of tibial lucency, 1 had 3 mm of tibial lucency, 1 had 1 mm of tibial lucency, and 1 had 4 mm of femoral lucency. Patients with loose beads had significantly lower knee scores than those patients without loose beads ( $p = 0.002$ , Student's  $t$ -test) (Table VI). Loose beads signifies that either the femoral or tibial prosthesis, or both, are loose, usually the tibial component in our series.

Another complication was the need for 1 or more transverse intercondylar screws because of intraoperative condylar splitting. Of the 4 instances (7%) of condylar splitting, 3 were in the tibia and 1 was in the femur. These "splits" reduced the early scores at 3 and 6 months but did not alter the long-term scores when compared

with the group as a whole (i.e., 1 year or longer). Only 1 cementless unicondylar knee (1.8%) was booked for revision; however, the criteria for revision vary from among surgeons. The patient was a 56-year-old man who was at a 90-month follow-up. Clinically, he had a knee score of 54,  $120^\circ$  range of motion, a pain score of 10, 5

**Table I**

Clinical Results of Cementless Unicondylar Knee Arthroplasty According to Patient Age\*

Clinical result	Age, yr		p value
	≤ 60 (n = 7)	> 60 (n = 50)	
Pain score	38.6 (11.8)	44.9 (6.7)	0.17
Range of motion, °	100.7 (9.8)	103.5 (9.3)	0.32
Knee score	80.6 (14.5)	89.1 (7.7)	0.11

\*Results are means (and standard deviations).  
n = no. of knees operated on.

**Table II**

Clinical Results of Cementless Unicondylar Knee Arthroplasty According to Patient Weight\*

Clinical result	Weight, kg		p value
	≤ 90 (n = 40)	> 90 (n = 17)	
Pain score	44.8 (7.1)	42.6 (8.9)	0.20
Range of motion, °	103.8 (9.7)	101.8 (8.3)	0.23
Knee score	88.6 (9.1)	86.6 (9.8)	0.22

\*Results are means (and standard deviations).  
n = no. of knees operated on.

**Table III**

Clinical Results of Cementless Unicondylar Knee Arthroplasty According to Patient Gender\*

Clinical result	Gender		p value
	Male (n = 37)	Female (n = 20)	
Pain score	44.5 (7.5)	43.5 (8.0)	0.33
Range of motion, °	103.4 (8.9)	102.8 (10.2)	0.41
Knee score	88.9 (8.6)	86.4 (9.9)	0.17

\*Results are means (and standard deviations).  
n = no. of knees operated on.

mm of radiolucency in the tibia with none in the femur, and loose beads on the radiograph.

Cementless versus cemented UKA

Knee scores for individual patients were categorized as excellent (85 to 100), good (70 to 84), fair (60 to 69) or poor (less than 60). Of the 57 knees seen in our follow-up group, there were 43 (75%) excellent results, 12 (21%) good results, 1 (2%) fair result and 1 (2%) poor result. With use of the  $\chi^2$  test, these results were found to be comparable to those of Sisto and colleagues<sup>1</sup> on the cemented Johnson & Johnson Robert Brigham (PFC) unicondylar knee system (Fig. 3) ( $p = 0.007$ ). In 61 knees, they reported 42 (69%) excellent results, 7 (11%) good results, 6 (10%) fair results and 6 (10%) poor results.

Radiographically, only 4 (7%) of our

cementless knees had more than 1 mm of radiolucency in the femoral components compared with 17 (28%) of the femoral components in the cemented femoral components reported by Sisto and colleagues<sup>1</sup> ( $p = 0.0001$ ). Two of our femoral components had only 2 mm of radiolucency, 1 had 3 mm of radiolucency and 1 had 4 mm of radiolucency. Twelve (21%) of the cementless tibial components had radiolucent lines greater than 1 mm, compared with 12 (19%) of the cemented tibial components reported by Sisto and colleagues<sup>1</sup> ( $p = 0.39$ ). Twenty-eight (49%) of our cementless tibial components showed at least 1 mm of radiolucency.

DISCUSSION

UKA remains one of the most controversial procedures in knee surgery and has yet to find its proper niche. Insall and Aglietti,<sup>15</sup> Insall and Walker<sup>16</sup>



FIG. 3. Cemented unicondylar knee prosthesis (Johnson & Johnson PFC).

and Laskin<sup>17</sup> were among the first of its critics. Padgett and colleagues<sup>30</sup> described UKA as not a simple bone-stock-sparing procedure but rather major reconstructive surgery that was difficult to revise. Others have shown excellent results with both HTO and TKA, so it is easy to understand why critics find little place for UKA in the treatment of osteoarthritis.

Advocates of UKA will be quick to point out that the reports of Insall and Laskin are the only 2 negative reviews and there are many long-term follow-up reports with more favourable results. The majority of these studies were performed on patients receiving cemented components of the Robert Brigham (PFC) or the older Marmor type.<sup>27</sup> Total cementless UKA is not rare,<sup>27</sup> although the infrequent mention in the literature might suggest rarity.

This paper is one of the largest reports of both short- and long-term results of UKA with cementless components. Although this study is cross-sectional in nature we felt it important to report our results as they stand. Only 1 author (R.E.E.) follows these patients on an annual basis and they were assessed only by him preoperatively. Realizing our limitations, we made several observations about our study population:

Table IV

Clinical Results of Cementless Unicondylar Knee Arthroplasty According to Duration of Follow-up\*

Clinical result	Follow-up, yr			p value
	< 2 (n = 24)	2-5 (n = 19)	> 5 (n = 14)	
Pain score	46.0 (4.4)	41.1 (9.1)	45.0 (9.0)	0.09
Range of motion, °	104.6 (10.1)	102.1 (8.0)	102.1 (9.7)	0.62
Knee score	90.3 (5.4)	85.0 (2.2)	88.2 (12.5)	0.17

\*Results are means (and standard deviations).  
n = no. of knees operated on.

Table V

Radiologic Results of Cementless Unicondylar Knee Arthroplasty : Knee Score According to Degree of Radiolucency

Radiolucency, mm	No. of patients	Knee score*
0	27	91.1 (5.7)†
1	16	86.6 (11.9)
> 1	14	83.9 (9.6)†

\*Mean and standard deviation  
† = 0.03.

Table VI

Radiologic Results of Cementless Unicondylar Knee Arthroplasty : Knee Score According to Presence of Loose Beads

Loose beads	No. of patients	Knee score*
Present	5	76.4 (14.5)
Absent	52	89.2 (7.1)

\*Mean and standard deviation  
p = 0.002.

- We had a very satisfied group of patients as a whole.
- Our group had a low rate of revision (1.8%), and since the only absolute indication for revision is pain, they had good pain relief
- Although our study was never designed to be comparative in nature, we did attempt to compare it to a historical control group in which cemented unicondylar knee components were used.<sup>1</sup> We realize it is impossible to make any concrete conclusions from this comparison, but our cementless components were comparable in terms of excellent, good, fair and poor clinical ratings.
- The cementless femur had less radiolucency than the cemented femur.
- With respect to the tibial component, there were similar percentages of components with greater than 1 mm of radiolucency in the cemented and cementless groups. However, approximately 50% of cementless tibial components had at least 1 mm of radiolucency. If only 1 mm of radiolucency was detected, it was usually seen in zone 1 anteriorly on the lateral view of the tibia and was associated with a posterior slope of the tibial component. This posterior sloping may increase the load on the posterior portion of the polyethylene.
- When the patients with only 1 mm of radiolucency were compared to those with no radiolucency, knee scores were not significantly different. While studying revised UKA polyethylene components, McCallum and Scott<sup>34</sup> were able to describe a particular type of anterior wear mainly on the periphery similar to that seen in prearthroplasty medial compartment osteoarthritis. Directing the majority of the knee load posteriorly by decreasing the  $\sigma$  angle may decrease the amount of wear

on the anterior portion of the polyethylene allowing it to last longer.

- Five (9%) knees in our study had evidence of loose beads within the knee joint, and these patients had significantly lower knee scores than patients without loose beads. The presence of loose beads signifies that either the femoral or tibial prostheses (or both) are loose, usually the tibial component. It was the tibial component in our series that had significantly more radiolucency, perhaps indicating the need for a cemented tibial component.
- Another complication in our study was the need for a transverse intercondylar screw because of intraoperative condylar splitting. Of the 4 instances (7%) of condylar splitting, 3 were in the tibia and 1 was in the femur, possibly owing to the small surface area available on the tibia for impaction of the cementless components used in our series. Placement of the screws must be precise as there again is very little area for good cortical purchase. Cement would alleviate the need for impaction, but 3 screws should still be used with this particular design. Mikovsky and colleagues<sup>35</sup> studied 3 different cementing techniques of the same tibial components that we investigated and found that deep penetration on a prepared (drilled with pulsatile lavage) tibial cancellous surface provided the best fixation in terms of micromotion. They did not compare cement and screw fixation, but this should be studied in the future if the component design is changed.

No matter what type of unicondylar system is chosen, the key to success is proper patient selection. In a follow-up to Kozinn and Scott's report, Chestnut<sup>13</sup> described a protocol to predict which patients with pri-

marily unicompartmental disease would be good candidates for UKA. He was able to predict good UKA candidates with excellent precision, based on historical, physical and roentgenographic findings. His historical criteria were pain in one compartment, minimal knee instability and minimal patellar symptoms. Predictive physical findings included mild laxity to varus or valgus stress at 30° of flexion that can be corrected to midline, normal hip motion, negative McMurray test in the opposite compartment, flexion contracture less than 15°, normal cruciate and collateral ligaments, and no findings suggesting causes other than osteoarthritis. Radiographic criteria included unicompartmental joint space loss on a 45° flexion posterior-anterior film or on stress films (if indicated), no significant subluxation of femur from tibia, no degenerative changes or chondrocalcinosis in the opposite compartment and mild patellofemoral changes on the Merchant view. Chestnut also suggested that patients up to 55 years of age should receive either HTO, UKA or TKA, whereas those over 55 should receive UKA or TKA, depending on whether the disease process is unicompartmental or tricompartmental. As the patient approaches 70 years of age, moderate changes in the 2 uninvolved compartments are accepted, because good follow-up results have been reported.

Our results support this protocol, because age, weight and gender were not strict contraindications to UKA in our study group and were not found to affect our clinical results. Despite popular belief, UKA is not restricted to young, healthy women or older, sedentary women. It therefore may have an important role in the surgical treatment of unicompartmental osteoarthritis for any patient who meets the criteria outlined by Chestnut<sup>13</sup> and Kozinn and Scott.<sup>25</sup>

References

1. Sisto DJ, Blazina ME, Heskiöff D, Hirsh LC. Unicompartment arthroplasty for osteoarthritis of the knee. *Clin Orthop* 1993;286:149-53.
2. Rand JA. Role of arthroscopy in osteoarthritis of the knee. *Arthroscopy* 1991;7(4):358-63.
3. Emerson RH Jr, Potter T. The use of the McKeever metallic hemiarthroplasty for unicompartmental arthritis. *J Bone Joint Surg [Am]* 1985;67(2): 208-12.
4. Aglietti P, Rinonapoli E, Stringa G, Taviani A. Tibial osteotomy for the varus osteoarthritic knee. *Clin Orthop* 1983;176:239-51.
5. Matthews LS, Goldstein SA, Malvitz TA, Katz BP, Kaufer H. Proximal tibial osteotomy. Factors that influence the duration of satisfactory function. *Clin Orthop* 1988;229:193-200.
6. Gill T, Schemitsch EH, Brick GW, Thornhill TS. Revision total knee arthroplasty after failed unicompartmental knee arthroplasty or high tibial osteotomy. *Clin Orthop* 1995;321: 10-8.
7. Broughton NS, Newman JH, Baily RA. Unicompartmental replacement and high tibial osteotomy for osteoarthritis of the knee. A comparative study after 5-10 years' follow-up. *J Bone Joint Surg [Br]* 1986;68(3):447-52.
8. Kalpan RR, Volz R. Osteotomy versus unicompartmental prosthetic replacement in the treatment of unicompartmental arthritis of the knee. *Orthopedics* 1982;5:989-94.
9. Goldberg VM, Figgie MP, Figgie HE 3rd, Heiple KG, Sobel M. Use of a total condylar knee prosthesis for treatment of osteoarthritis and rheumatoid arthritis. Long-term results. *J Bone Joint Surg [Am]* 1988;70(6):802-11.
10. Insall JN, Hood RW, Flawn LB, Sullivan DJ. The total condylar knee prosthesis in gonarthrosis. A five to nine-year follow-up of the first one hundred consecutive replacements. *J Bone Joint Surg [Am]* 1983;65(5):619-28.
11. Rand JA, Ilstrup DM. Survivorship analysis of total knee arthroplasty. Cumulative rates of survival of 9200 total knee arthroplasties. *J Bone Joint Surg [Am]* 1991;73(3):397-409.
12. Cameron HU, Jung YB. A comparison of unicompartmental knee replacement with total knee replacement. *Orthop Rev* 1988;17(10):983-8.
13. Chestnut WJ. Preoperative diagnostic protocol to predict candidates for unicompartmental arthroplasty. *Clin Orthop* 1991;273:146-50.
14. Simmons S, Lephart S, Rubash H, Pifer GW, Barrack R. Proprioception after unicondylar knee arthroplasty versus total knee arthroplasty. *Clin Orthop* 1996;331:179-84.
15. Insall J, Aglietti P. A five to seven-year follow-up of unicondylar arthroplasty. *J Bone Joint Surg [Am]* 1980;62(8): 1329-37.
16. Insall J, Walker P. Unicondylar knee replacement. *Clin Orthop* 1976;120: 83-5.
17. Laskin RS. Unicompartmental tibiofemoral resurfacing arthroplasty. *J Bone Joint Surg [Am]* 1978;60(2):182-5.
18. Marmor L. Unicompartmental and total knee arthroplasty. *Clin Orthop* 1985;192:75-81.
19. Marmor L. Marmor modular knee in unicompartmental disease. Minimum four-year follow-up. *J Bone Joint Surg [Am]* 1979;61(3):347-53.
20. Scott RD, Cobb AG, McQueary FG, Thornhill TS. Unicompartmental knee arthroplasty. Eight- to 12-year follow-up evaluation with survivorship analysis. *Clin Orthop* 1991;271:96-100.
21. Scott RD, Santore RF. Unicondylar unicompartmental replacement for osteoarthritis of the knee. *J Bone Joint Surg [Am]* 1981;63(4):536-44.
22. Nilsson KG, Dalen T. Comparison of 3 types of unicompartmental knee arthroplasty — a prospective randomized RSA study. *Acta Orthop Scand* 1997;68(Suppl 274):81-3.
23. Stockelman RE, Pohl KP. The long-term efficacy of unicompartmental arthroplasty of the knee. *Clin Orthop* 1991;271:88-95.
24. Stern SH, Becker MW, Insall JN. Unicondylar knee arthroplasty. An evaluation of selection criteria. *Clin Orthop* 1993;286:143-8.
25. Kozinn SC, Scott RD. Current concepts review: unicondylar knee arthroplasty. *J Bone Joint Surg [Am]* 1989; 71:145-9.
26. Corpe RS, Engh GA. A quantitative assessment of degenerative changes acceptable in the unoperated compartments of knees undergoing unicompartmental replacement. *Orthopedics* 1990;13:319-25.
27. Swank M, Stulberg SD, Jiganti J, Machairas S. The natural history of unicompartmental arthroplasty. An eight-year follow up study with survivorship analysis. *Clin Orthop* 1993; 286:130-42.
28. Insall JN, Dorr LD, Scott RD, Scott WN. Rationale of the Knee Society clinical rating system. *Clin Orthop* 1989;248:13-4.
29. Ewald FC. The Knee Society total knee arthroplasty roentgenographic evaluation and scoring system. *Clin Orthop* 1989;248:9-12.
30. Padgett DE, Stern SH, Insall JN. Revision total knee arthroplasty for failed unicompartmental replacement. *J Bone Joint Surg [Am]* 1991;73(2):186-90.
31. Laurencin CT, Zelicof SB, Scott RD, Ewald FC. Unicompartmental versus total knee arthroplasty in the same patient. A comparative study. *Clin Orthop* 1991;273:151-6.
32. Rougraff BT, Heck DA, Gibson AE. A comparison of tricompartmental and unicompartmental arthroplasty for the treatment of gonarthrosis. *Clin Orthop* 1991;273:157-64.
33. Robertsson O, Borgquist L, Knutson K, Lewold S, Lidgren L. Economical aspects of using tricompartmental instead of unicompartmental prostheses for gonarthrosis. *Acta Orthop Scand* 1997;68(Suppl 274):84-90.
34. McCallum JD 3rd, Scott RD. Duplication of medial erosion in unicompartmental knee arthroplasties. *J Bone Joint Surg [Br]* 1995;77(5):726-8.
35. Miskovsky C, Whiteside LA, White SE. The cemented unicondylar knee arthroplasty. An in vitro comparison of three cement techniques. *Clin Orthop* 1992;284:215-20.