

SOFT-TISSUE CASE 30. PRESENTATION

A 49-year-old man presented to the Emergency Department with pain in his right hip after falling 3 m off a ladder. The results of abdominopelvic computed tomography are shown in Fig. 1. What is the diagnosis?

For the answer see page 420.

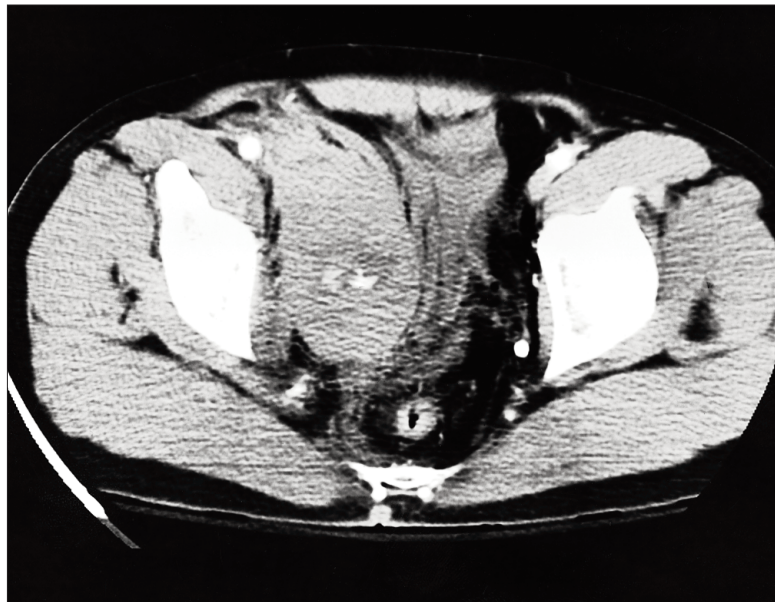


FIG. 1

Section Editor: Lawrence A. Stein, MD

Submitted by: L. Shulman, MSc, *H. Mahallati, MD, † and R. Gray, MD, † *Student, Faculty of Medicine, University of Calgary, and †Department of Diagnostic Imaging, Foothills Hospital, Calgary, Alta.

Correspondence to: Dr. Robin Gray, Department of Diagnostic Imaging, Foothills Hospital, 1403-29th St. NW, Calgary AB T2N 2T9; fax 780 670-1969, robin.gray@crha-health.ab.ca

Submissions to *Radiology for the Surgeon*, soft-tissue section, should be sent to Dr. Lawrence A. Stein, Department of Diagnostic Radiology, Royal Victoria Hospital, 687 Pine Ave. W, Montreal QC H3A 1A1.

© 1999 Canadian Medical Association

Want to search **MEDLINE?**

OSLER (Ovid Search: Link to Electronic Resources) provides CMA members with

- free access to MEDLINE
- free access to HealthStar, AIDSLINE and CancerLit
- free librarian support

Almost 5000 physicians — almost 10% of CMA members — are using the CMA's free online search service. To register: www.cma.ca/osler

For information:

Deidre Green

OSLER Support Librarian

800 663-7336 x2255

cmalibrary@sympatico.ca

