

### ENDOMETRIOMA SIMULATING INGUINAL HERNIA: CASE REPORTS

Anthony C.N. Li, MB BS; Wing-Tai Siu, MB BCh; Michael K.W. Li, MB BS

General surgeons may encounter endometriosis when extrapelvic forms of the disease mimic general surgical diseases. Although some patients present with typical cyclic symptoms associated with their extrapelvic disease, diagnosis can be difficult in those who have no menstrual symptoms. We describe 2 patients with inguinal endometrioma who presented with clinical features of inguinal hernia.

#### CASE REPORTS

##### Case 1

A 42-year-old woman, para 2, presented with a history of right groin pain for 1 month. The pain was associated with a small swelling, which fluctuated in size. Her symptoms were noncyclical and were worse on prolonged standing. On physical examination, no abnormality was found that could be related to her symptoms. She was managed conservatively. At 3-month follow-up, she complained of pain in the same area, but again physical examination revealed no abnormality, nor did ultrasonography. At a subsequent follow-up visit 3 months later a 2-cm nontender, reducible mass was found above and lateral to the right pubic tubercle. A diagnosis of right indirect inguinal hernia was made.

At operation, a bluish nodule, 1 cm in diameter attached to the round ligament (Fig. 1) was excised, and the deep inguinal ring was closed. Histologically, the lesion showed the characteristic features of an endometrioma. At gynecologic assessment,

postoperatively, bilateral chocolate cysts were found. These were removed. At follow-up 1 year postoperatively, the patient was well with no recurrence of the endometriosis.

##### Case 2

A 27-year-old nulliparous woman presented with a 3-month history of right inguinal swelling, which was sometimes painful. On physical examination, a 2-cm nontender reducible mass was found over the right external inguinal ring. Right inguinal hernia was diagnosed. The operative findings were similar to those seen in Case 1. The mass was excised and found to be an endometrioma. On subsequent gynecologic examination no genital endometriosis was found and there was no recurrence at 1-year follow-up.

#### DISCUSSION

Endometriosis is a common gynecologic condition, occurring in 8% to 15% of women of reproductive age.<sup>1</sup> The rate of nongenital endometriosis is, however, much rarer, occurring in 1% to 2% of patients with pelvic endometriosis.<sup>1</sup> Conversely, extragenital endometriosis can occur in the absence of genital disease as in our Case 2, but it is seldom reported. Endometrioma has been mistaken for inguinal, ventral or umbilical hernia, lymphadenopathy or soft-tissue tumour of the extremities. Endometriosis in the inguinal area was first described by Allen in 1896, and since that time only 30 cases have

been reported, all in women in their reproductive years.<sup>2</sup> Such endometriomas arise from the round ligament, usually on the right side as in our cases. One theory of the histogenesis of these endometriomas is progression of the condition down the ligament into the inguinal canal,<sup>3</sup> although its presence in the inguinal canal was not always demonstrated, as in our Case 2. Differential diagnoses of an inguinal mass in women include inguinal hernia, femoral hernia, a lymph node, lipoma and hydrocele of the canal of Nuck.

Symptoms of extrapelvic endometriosis, often diverse and puzzling, usually result from functioning endometrial tissue or scarring at the affected site. The location of the endometriosis, not the size of the implant, determines the symptoms. Many women with extensive endometriosis are asymptomatic, yet a small focus of disease in a particular location can produce disturbing problems.<sup>3</sup> Clues to the presence of endometriosis include pain, bleeding or organ dysfunction related to menstruation. Noncyclical symptoms can

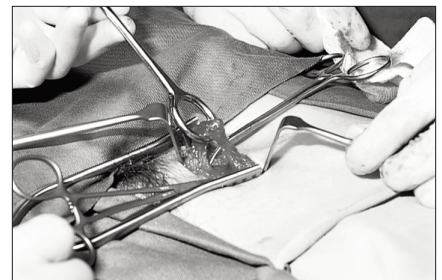


FIG. 1. Case 1. Operative view showing the endometrioma attached to the round ligament.

From the Department of Surgery, Pamela Youde Nethersole Eastern Hospital, Chai Wan, Hong Kong

Accepted for publication Feb. 3, 1998.

Correspondence to: Mr. M.K.W. Li, Department of Surgery, Pamela Youde Nethersole Eastern Hospital, No. 3 Lok Man Rd., Chai Wan, Hong Kong; fax 852 25153195

© 1999 Canadian Medical Association

confuse the clinician. It has been proposed that these extragenital lesions, especially those further away from the uterus, tend to lose their hormonal receptors and response, hence the lack of cyclical symptoms.<sup>4</sup> Ultrasonography has been used to aid in the diagnosis of endometrioma, which can occur as a cystic-solid lesion.<sup>5</sup>

The treatment is surgical excision of the mass. Local recurrence at the surgical scar has been reported.<sup>6</sup> Patients should undergo a full gynecologic assessment to search for pelvic endometriosis.

Since extrapelvic endometrioma can mimic general surgical conditions, it is important that general surgeons be familiar

with the unusual types. Awareness of endometriosis is essential to diagnosis and must be considered in any woman of reproductive age with atypical presentation of inguinal hernia. Even then, preoperative diagnosis is sometimes difficult and groin exploration may be necessary.

## References

1. Mitchell GW. Extrapelvic endometriosis. In: Schenken RS, editor. *Endometriosis: contemporary concepts in clinical management*. Philadelphia: J.B. Lippincott; 1989. p. 307-28.
2. Sataloff DM, La Vorgna KA, McFarland MM. Extrapelvic endometriosis presenting as a hernia: clinical reports and review of the literature. *Surgery* 1989;105(1):109-12.
3. Luciano AA, Pitkin RM. Endometriosis: approaches to diagnosis and treatment. *Surg Annu* 1984;16:297-312.
4. Markham SM, Carpenter SE, Rock JA. Extrapelvic endometriosis. *Obstet Gynecol Clin North Am* 1989;16(1):193-219.
5. Athey PA, Diment DD. The spectrum of sonographic findings in endometriomas. *J Ultrasound Med* 1989;8(9):487-91.
6. Koger KE, Shatney CH, Hodge K, McCleathan JH. Surgical scar endometrioma. *Surg Gynecol Obstet* 1993;177(3):243-6.

## Books and Other Media Received

### Livres et autres documents reçus

This list is an acknowledgement of books and other media received. It does not preclude review at a later date.

Cette liste énumère les livres et autres documents reçus. Elle n'en exclut pas la critique à une date ultérieure.

**Angiogenesis and Cardiovascular Disease.** Edited by J. Anthony Ware and Michael Simons. 360 pp. Illust. Oxford University Press Inc., New York; Oxford University Press Canada, Toronto. 1999. Can\$108. ISBN 0-19-511235-0

**Care of the Critically Ill Surgical Patient.** Edited by Iain D. Anderson. 176 pp. Illust. Arnold, London; Oxford University Press Canada, Toronto. 1999. Can\$72. ISBN 0-340-70092-0

**Emergency Abdominal Surgery in Infancy, Childhood and Adult Life.** 3rd edition. Edited by Peter F. Jones, Zygmunt H. Krukowski and George G. Youngson. 556 pp. Illust. Chapman & Hall Medical, London; Oxford University Press Canada, Toronto. 1998. Can\$104. ISBN 0-412-81950-3

**Handbook of Breast Surgery.** Adrian Shervington Ball and Peter M. Arnstein. 166 pp. Illust. Arnold, London; Oxford

University Press Canada, Toronto. 1999. Can\$56. ISBN 0-340-74161-9

**Management of Abdominal Hernias.** 2nd edition. H. Brendan Devlin and Andrew Kingsnorth, with Patrick J. O'Dwyer and Karen Bloor. 324 pp. Illust. Chapman & Hall Medical, London; Oxford University Press Canada, Toronto. 1998. Can\$216. ISBN 0-412-73820-1

**Minimal Access Thoracic Surgery.** Edited by Klaus Manncke and R. David Rosin. 284 pp. Illust. Chapman & Hall, London; Oxford University Press Canada, Toronto. 1998. Can\$176. ISBN 0-412-81600-8

**Operative Maxillofacial Surgery.** Edited by John D. Langdon and Mohan F. Patel. 521 pp. Illust. Chapman & Hall Medical, London; Oxford University Press Canada, Toronto. 1998. Can\$360. ISBN 0-412-56000-3

**Surgery for Ischaemic Heart Disease.** Edited by Ravi Pillai and John E.C. Wright. 296 pp. Illust. Oxford University Press, Oxford; Oxford University Press Canada, Toronto. 1999. Can\$201.95. ISBN 0-19-262466-0

**Surgical Management of Cutaneous Ulcers and Pressure Sores.** Edited by Bok Y. Lee and Burton L. Herz. 263 pp. Illust. Chapman & Hall (International Thomson Publishing Asia), Singapore; Oxford University Press Canada, Toronto. 1998. Can\$152. ISBN 0-412-99421-6

**Textbook of Disorders of the Musculoskeletal System.** An Introduction to Orthopaedics, Fractures and Joint Injuries, Rheumatology, Metabolic Bone Disease and Rehabilitation. 3rd edition. Robert B. Salter. 687 pp. Illust. Williams & Wilkins, Baltimore. 1999. Can\$79.95. US\$49.95. ISBN 0-683-07499-7

**Varicose Veins.** Harold Ellis and Peter Taylor. 122 pp. Illust. Greenwich Medical Media, London; Oxford University Press Canada, Toronto. 1999. Can\$28.95. ISBN 1-900151-677

**Vascular Surgery.** P.M. Lamont, C.P. Shearman and D.J.A. Scott. 140 pp. Illust. Oxford University Press Inc., New York; Oxford University Press Canada, Toronto. 1999. Can\$201.95. ISBN 0-19-262523-3