

MUSCULOSKELETAL CASE 2: PRESENTATION

A 27-year-old woman presented in the emergency department with a painful right shoulder held in pronounced abduction after a fall while playing squash.

Radiographs of the shoulder were obtained (Fig. 1). Based on the radiograph and the patient's history, what is your clinical diagnosis?

For the answer, see page 64.

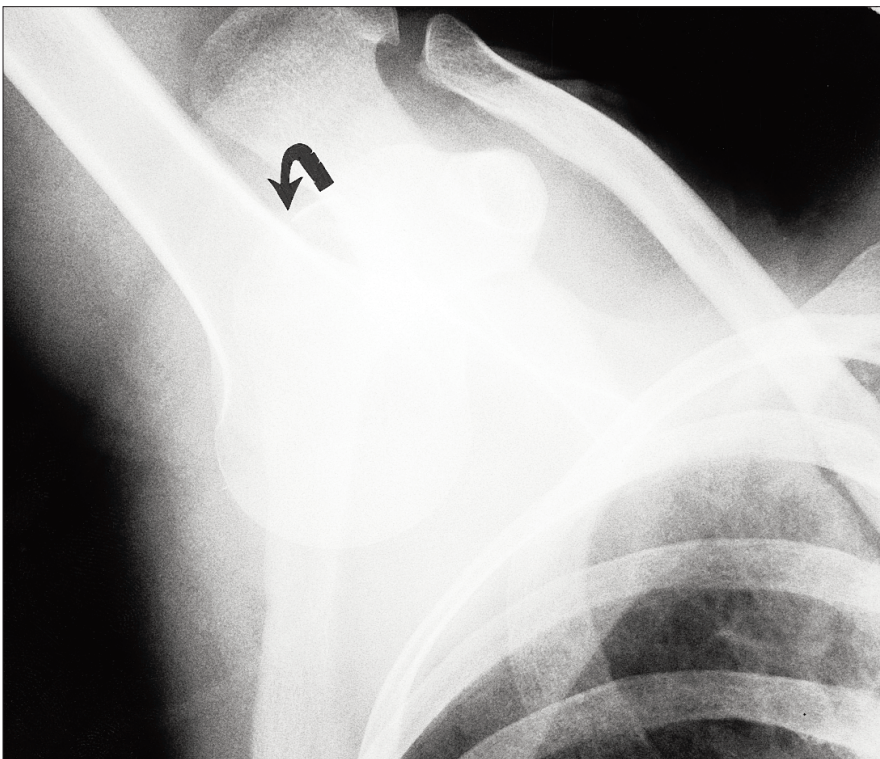


FIG. 1

Section Editor: Peter L. Munk, MD

Submitted by Peter L. Munk, MD, and Mark J. Lee, BSc

Correspondence to Dr. Peter L. Munk, Professor, Department of Radiology, Vancouver General Hospital, Vancouver Hospital and Health Sciences Centre, 855 West 12th Ave., Vancouver BC V5Z 1M9.

© 1999 Canadian Medical Association