

NEOPLASTIC PULMONARY EMBOLISM

A 44-year-old woman complained of a tender mass in the right buttock. The mass was excised and found to be a high-grade round cell sarcoma. The surgical margins contained tumour cells so she was referred to our cancer centre for further assessment and treatment. Her complaints were of persistent buttock pain and pleuritic pain in the left side of the chest. On physical examination a residual mass in the right buttock and

swelling of the right lower extremity were noted. Doppler ultrasonography confirmed a deep venous thrombosis. Magnetic resonance imaging showed a large residual right gluteal mass with intrapelvic extension. Staging computed tomography of the chest showed bilateral lower lobe lesions. The appearance of the lesion on the left was consistent with a pulmonary infarct (Fig. 1), but the appearance of the lesion on the right was nonspecific (Fig. 2).

A multidisciplinary plan, formulated to treat the sarcoma, included induction treatment with ifosfamide-based chemotherapy and radiotherapy before surgical resection. However, the aggressiveness of treatment, especially the surgical aspects, would be influenced by the presence or absence of metastatic disease in distant organs. The patient therefore underwent thoracoscopic wedge resection of the right lower lobe abnormality. Histologic examination of the excised specimen showed pulmonary infarction from an intravascular high-grade round cell sarcoma embolus.

Neoplastic pulmonary embolism is an uncommon and often forgotten cause of pulmonary infarction in can-

cer patients.^{1,2} Large tumour emboli can cause sudden death, and smaller recurrent emboli can cause pulmonary hypertension and cor pulmonale. Although tumour emboli to the lungs cause pulmonary infarction, they do not necessarily lead to viable pulmonary parenchymal metastases.³ Complete resection of the primary tumour, if possible, will best prevent the occurrence of neoplastic emboli. However, manipulation of the tumour at operation may produce massive tumour embolism and sudden intraoperative death.

References

1. King MB, Harmon KR. Unusual forms of pulmonary embolism. *Clin Chest Med* 1994;15:561-80.
2. Domanski MJ, Cunnion RE, Fernicola DJ, Roberts WC. Fatal cor pulmonale caused by extensive tumor emboli in the small pulmonary arteries without emboli in the major pulmonary arteries or metastases in the pulmonary parenchyma. *Am J Cardiol* 1993;72:233-4.
3. Yeatman TJ, Nicolson GL. Molecular basis of tumor progression: mechanisms of organ-specific tumor metastasis. *Semin Surg Oncol* 1993;9:256-63.

Section Editors: David P. Girvan, MD, and Nis Schmidt, MD

Submitted by John D. Urschel, MD, Division of Surgical Oncology, Roswell Park Cancer Institute, Buffalo NY

Correspondence to: Dr. John D. Urschel, Thoracic Surgical Oncology, Roswell Park Cancer Institute, Elm and Carlton Streets, Buffalo NY 14263-0001, USA; tel. 716 282-4059, fax 716 282-4186

Submissions to *Surgical Images* should be sent to Dr. David P. Girvan, Victoria Hospital Corporation, PO Box 5375, Station B, London ON N6A 5A5 or to Dr. Nis Schmidt, Department of Surgery, St. Paul's Hospital, 1081 Burrard St., Vancouver BC V6Z 1Y6, with a copy of the submitting letter to Dr. Jonathan L. Meakins, Rm. S10.34, Royal Victoria Hospital, 687 Pine Ave. W, Montreal QC H3A 1A1

© 1998 Canadian Medical Association

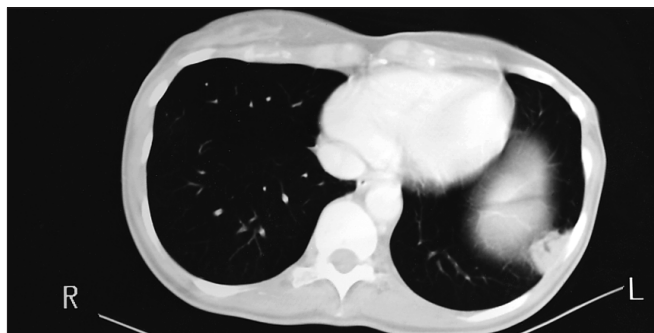


FIG. 1

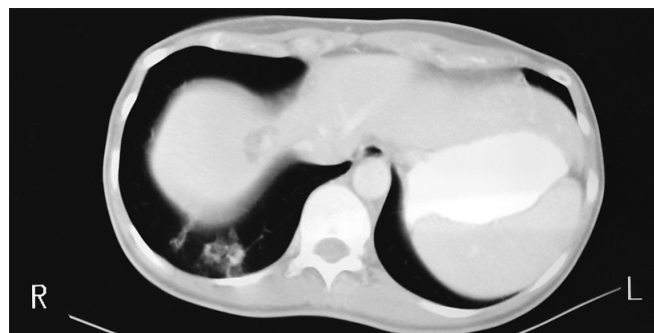


FIG. 2