

Surgical Images

Imagier chirurgical

PNEUMATOSIS INTESTINALIS

A previously healthy 30-year-old woman, who was receiving loxapine and fluvoxamine therapy for psychotic depression, left hospital and took an overdose of acetaminophen. She was treated in the Emergency Department with charcoal and acetylcysteine. On admission to hospital she was noted to have a distended abdomen and generalized abdominal tenderness. The initial abdominal films revealed no free air or pneumatosis intestinalis. She was observed during the day but failed to improve. Investigations included repeat abdominal radiography (Fig. 1) and CT (Fig. 2), which revealed pneumatosis intestinalis involving the ascending colon (between arrowheads). Because of increasing abdominal tenderness and

the radiologic findings, urgent laparotomy was carried out, confirming the apparent ischemia of the colon with palpable emphysema of the bowel wall. The ascending and transverse portions of the colon were resected. Histologic examination of the resected specimen suggested an ischemic event but no identifiable disease.

Pneumatosis intestinalis is an uncommon but significant condition in adults in which gas is found in a linear or cystic form in the submucosa or the subserosa of the bowel wall. As such, pneumatosis intestinalis is only a sign and must be interpreted in light of the clinical findings because it may be found in various scenarios: in patients who are otherwise healthy, and associ-

ated with pyloric stenosis, jejunoileal bypass, progressive systemic sclerosis, transplantation, chemotherapy, immunosuppression (including AIDS), obstructive pulmonary disease and finally, as in our case, with frank ischemic bowel.^{1,2}

References

1. Heng Y, Schuffler MD, Haggitt RC, Rohrmann CA. Pneumatosis intestinalis: a review [review]. *Am J Gastroenterol* 1995;90(10):1747-58.
2. Wood BJ, Kumar PN, Cooper C, Silverman PM, Zeman RK. Pneumatosis intestinalis in adults with AIDS: clinical significance and imaging findings. *AJR Am J Roentgenol* 1995;165(6):1387-90.

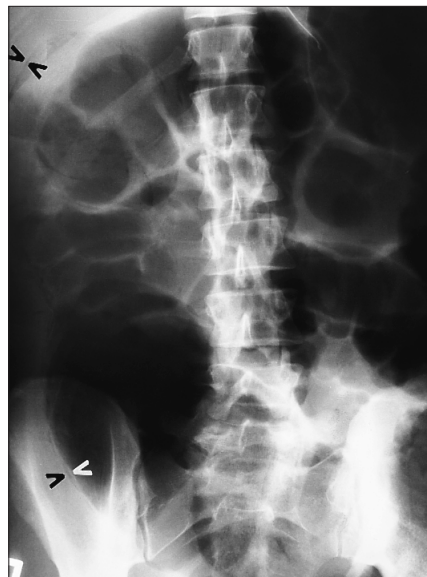


FIG. 1

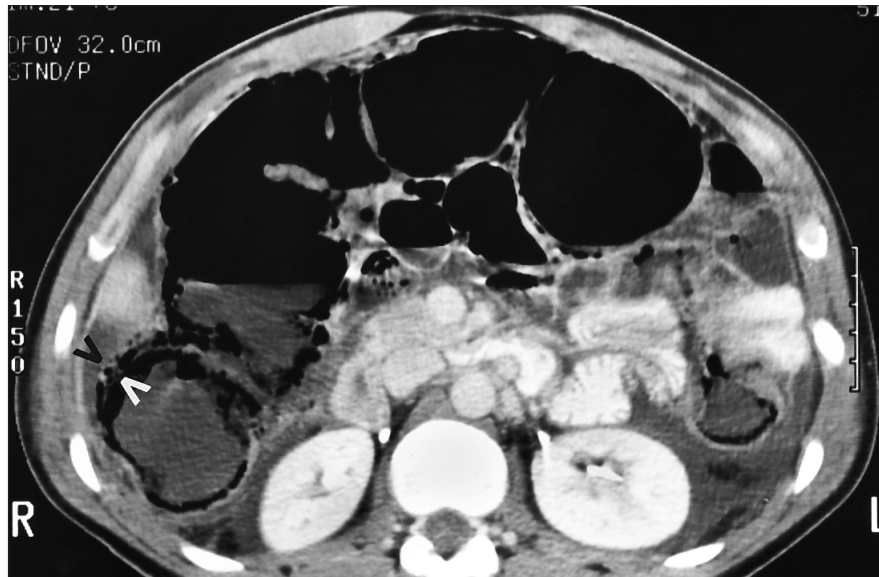


FIG. 2

Section Editors: David P. Girvan, MD and Nis Schmidt, MD

Submitted by R. Matthew Smith, MD, Kenneth W. Gow, BSc, BSc(Med), and John K. MacFarlane, MD CM, MSc, Department of Surgery, St. Paul's Hospital and the University of British Columbia, Vancouver, BC

Submissions to *Surgical Images* should be sent to Dr. David P. Girvan, Victoria Hospital Corporation, PO Box 5375, Station B, London ON N6A 5A5 or to Dr. Nis Schmidt, Department of Surgery, St. Paul's Hospital, 1081 Burrard St., Vancouver BC V6Z 1Y6, with a copy of the submitting letter to Dr. Jonathan L. Meakins, Rm. S10.34, Royal Victoria Hospital, 687 Pine Ave. W, Montreal QC H3A 1A1.

© 1997 Canadian Medical Association