

Meta-analysis of sentinel lymph node biopsy at the time of prophylactic mastectomy of the breast

Wen-Bin Zhou, MD*

Xiao-An Liu, MD*

Jun-Cheng Dai, PhD†

Shui Wang, MD*

From the *Department of Breast Surgery, The First Affiliated Hospital of Nanjing Medical University, and the †Department of Epidemiology and Biostatistics, Nanjing Medical University School of Public Health, Nanjing, China

Wen-Bin Zhou and Xiao-An Liu contributed equally to this work.

Accepted for publication
May 16, 2010

Correspondence to:

Dr. S. Wang

Department of Breast Surgery

The First Affiliated Hospital of Nanjing

Medical University

300 Guangzhou Rd.

210029 Nanjing

China

ws0801@hotmail.com

DOI: 10.1503/cjs.006010

Background: Prophylactic mastectomy is performed to decrease the risk of breast cancer in women at high risk for the disease. The benefit of sentinel lymph node biopsy (SLNB) at the time of prophylactic mastectomy is controversial, and we performed a meta-analysis of the reported data to assess that benefit.

Methods: We searched MEDLINE, EMBASE and the Cochrane Library databases from January 1993 to December 2009 for studies on patients who underwent SLNB at the time of prophylactic mastectomy. Two reviewers independently evaluated all the identified papers, and only retrospective studies were included. We used a mixed-effect model to combine data.

Results: We included 6 studies in this review, comprising a total study population of 1251 patients who underwent 1343 prophylactic mastectomies. Of these 1343 pooled prophylactic mastectomies, the rate of occult invasive cancer (21 cases) was 1.7% (95% confidence interval [CI] 1.1%–2.5%), and the rate of positive SLNs (23 cases) was 1.9% (95% CI 1.2%–2.6%). In all, 36 cases (2.8%, 95% CI 2.0%–3.8%) led to a significant change in surgical management as a result of SLNB at the time of prophylactic mastectomy. In 17 cases, patients with negative SLNs were found to have invasive cancer at the time of prophylactic mastectomy and avoided axillary lymph node dissection (ALND). In 19 cases, patients with positive SLNs were found not to have invasive cancer at the time of prophylactic mastectomy and needed a subsequent ALND. Of the 23 cases with positive SLNs, about half the patients had locally advanced disease in the contralateral breast.

Conclusion: Sentinel lymph node biopsy is not suitable for all patients undergoing prophylactic mastectomy, but it may be suitable for patients with contralateral, locally advanced breast cancer.

Contexte : La mastectomie prophylactique vise à réduire le risque de cancer du sein chez les femmes à risque élevé. L'avantage de la biopsie du ganglion lymphatique sentinelle (BGLS) au moment de la mastectomie prophylactique suscite la controverse et nous avons procédé à une méta-analyse des données qui ont fait l'objet de rapports afin d'évaluer l'avantage en question.

Méthodes : Nous avons cherché dans les bases de données MEDLINE, EMBASE et la Bibliothèque Cochrane, de janvier 1993 à décembre 2009, des études portant sur des patientes qui ont subi une BGLS au moment de la mastectomie prophylactique. Deux examinateurs ont évalué indépendamment toutes les études repérées et nous avons inclus seulement les études rétrospectives. Nous avons utilisé un modèle à effets mixtes pour combiner les données.

Résultats : Nous avons inclus dans cette analyse 6 études regroupant une population totale de 1251 patientes qui ont subi 1343 mastectomies prophylactiques. Parmi ces 1343 mastectomies prophylactiques regroupées, le taux de cancer envahissant occulte (21 cas) s'est établi à 1,7 % (intervalle de confiance [IC] à 95 %, 1,1 %–2,5 %) et le taux de GLS positifs (23 cas) a atteint 1,9 % (IC à 95 %, 1,2 %–2,6 %). Au total, les constatations dans 36 cas (2,8 %, IC à 95 %, 2,0 %–3,8 %) ont entraîné un changement important du traitement chirurgical à la suite de la BGLS pratiquée au moment de la mastectomie prophylactique. Dans 17 cas, on a découvert que les patientes dont la BGLS avait donné un résultat négatif avaient un cancer envahissant au moment de la mastectomie prophylactique et elles ont évité une ablation des ganglions lymphatiques axillaires (AGLA). Dans 19 cas, on a constaté que les patientes dont la BGLS avait donné un résultat positif n'avaient pas de cancer envahissant au moment de la mastectomie prophylactique et elles ont dû subir par la suite une AGLA. Sur les 23 patientes dont la BGLS avait produit un résultat positif, environ la moitié avaient la maladie localisée au stade avancé dans le sein controlatéral.

Conclusion : La biopsie du ganglion lymphatique sentinelle ne convient pas pour toutes les patientes qui subissent une mastectomie prophylactique, mais elle peut convenir pour celles qui ont un cancer localisé au stade avancé du sein controlatéral.

Prophylactic mastectomy has been widely performed to reduce the risk of breast cancer in women at high risk for the disease.¹⁻³ The indications for prophylactic mastectomy may include diffuse microcalcifications, lobular carcinoma in situ, atypical hyperplasia, multicentric contralateral breast cancer, strong family history and dense breast tissue,⁴ especially for the women with a strong family or personal history of breast cancer and a *BRCA1* or *BRCA2* gene mutation. The frequency of prophylactic mastectomy has increased with awareness of breast cancer genetics and the risk reduction afforded by surgical prophylaxis. Bilateral prophylactic mastectomy is widely performed on patients who are found to have a *BRCA1* or *BRCA2* mutation and has been proven to offer a survival benefit.⁵ Contralateral prophylactic mastectomy is chosen for patients with unilateral breast cancer to prevent possible cancer in the opposite breast.⁶⁻⁸ The procedure does not offer a survival benefit but is performed for local control of breast cancer, to reduce risk and to provide symmetry.

Sentinel lymph node biopsy (SLNB) has demonstrated more than 95% accuracy in staging axillary lymph nodes, and it has become an accepted standard of care for early-stage breast cancer.^{9,10} The applications of SLNB have expanded and include the evaluation of locally advanced breast cancer and prophylactic mastectomy. However, SLNB in the setting of prophylactic mastectomy remains controversial; some investigators have suggested that it is not routinely warranted and that few patients will benefit from SLNB at the time of prophylactic mastectomy. For instance, most patients with invasive cancer found in prophylactic mastectomy specimens have negative SLNs; in these patients SLNB allows unnecessary axillary lymph node dissection (ALND) to be avoided.¹¹ Sentinel lymph node biopsy at the time of prophylactic mastectomy can also identify positive SLNs in patients without invasive cancer; ALND is performed in these patients.

To our knowledge, there have been no recent randomized trials assessing SLNB at the time of prophylactic mastectomy; only a few generally retrospective studies have assessed this role of SLNB. We performed the present systematic review to give an overview of these studies and to provide recommendations regarding the role of SLNB at the time of prophylactic mastectomy.

METHODS

Literature search strategy

We searched the MEDLINE, EMBASE and Cochrane Library databases from January 1993 to December 2009. We selected 1993 as the starting point because it was the

year of the first publication on SLNB.¹² The following search terms were used: “prophylactic mastectomy,” “reduction mastectomy,” “contralateral mastectomy” and “bilateral mastectomy” combined with “lymph node,” “sentinel node,” “axillary surgery” and “axillary dissection.” We also reviewed the references in identified articles for possible inclusions. No language restrictions were applied. We contacted the corresponding authors for patient data when specific information required for the calculation of test characteristics was not included in the published reports. Two reviewers (W.-B.Z. and X.-A.L.) independently evaluated titles and abstracts of the identified papers. Potentially relevant articles were retrieved to review the full text.

Study inclusion criteria

To be included in this review, studies had to meet 3 criteria. First, the patients with no diagnosed cancer must have received prophylactic mastectomy (lobular carcinoma in situ not included) with or without immediate reconstruction. Second, the patients must have received SLNB at the time of prophylactic mastectomy, regardless of whether or not they subsequently received ALND. Patients who underwent prophylactic mastectomy or SLNB alone were excluded. Third, only retrospective studies were included in this meta-analysis.

Data extraction

Patient data were extracted from articles that met our inclusion criteria independently by the 2 reviewers. These data included the number of patients who underwent SLNB at the time of prophylactic mastectomy, the number of prophylactic mastectomies performed, the occult carcinoma identified in prophylactic mastectomy specimens and the number of positive SLNs. We recalculated the occult invasive cancer, positive SLN and benefit rates of SLNB at the time of prophylactic mastectomy according to standard definitions. The occult invasive cancer rate was defined as the number of occult invasive cancers identified in prophylactic mastectomy specimens divided by the number of prophylactic mastectomies performed. The positive SLN rate was defined as the number of prophylactic mastectomies with a positive SLN divided by the number of prophylactic mastectomies performed. The patients for whom invasive cancer was identified in prophylactic mastectomy specimens with a negative SLN could avoid ALND. The patients who had positive SLNs with no invasive cancer identified at the time of prophylactic mastectomy needed a subsequent ALND. In all, these patients experienced a

significant change in surgical management as a direct result of SLNB. We defined the benefit rate of SLNB as the number of negative SLNs at the time of prophylactic mastectomy in cases where invasive cancer was identified and the number of positive SLNs at the time of prophylactic mastectomy in cases where no invasive cancer was identified divided by the number of prophylactic mastectomies performed.

Statistical analysis

The positive proportion was used as the outcome measure for combined data. However, the distribution of proportion wasn't normal, so we performed Freeman–Tukey arcsine transformation to stabilize its variance. A χ^2 -based Q statistic test was performed to assess the between-study heterogeneity,¹³ and we considered the results to be significant at

$p < 0.05$. We used a fixed-effect model with the Mantel–Haenszel method to combine values from within a single study,¹⁴ whereas we used a random-effects model when there was between-study heterogeneity, which we explored using meta-regression analysis. Publication bias was investigated by funnel plot, in which the standard error of the odds ratio (OR) of each study was plotted against its OR. Funnel plot asymmetry was assessed using the Egger linear regression test, an approach to measure funnel plot asymmetry on the natural logarithm scale of the OR. The significance of the intercept was determined by the Student *t* test, as suggested by Egger,¹⁵ and we considered results to be significant at $p < 0.05$. All analyses were performed using Stata software version 9.2 (Stata Corporation). All statistical evaluations were made assuming a 2-sided test with a significance level of 0.05 unless stated otherwise.

RESULTS

Our initial search identified 112 potentially relevant articles, of which we screened the titles and abstracts. After full-text review of the 42 relevant studies, we identified 8 studies that met our first 2 inclusion criteria. Of these studies, the data of 1 study¹⁶ were updated by McLaughlin and colleagues¹⁷ in 2008, and 1 study¹⁸ was prospective, leaving 6 studies for inclusion in our analysis. The data were extracted from these 6 studies^{17,19–23} (Fig. 1). All the studies were conducted at a single institution. The total study population comprised 1251 patients who underwent SLNB at the time of prophylactic mastectomy. The main results of the 6 studies are summarized in Table 1.

A total of 1343 prophylactic mastectomies were performed in 1251 patients (Fig. 2). Unilateral prophylactic mastectomy was performed in 1159 patients (92.65%) and bilateral prophylactic mastectomy in 92 patients (7.35%). Most lymphatic mapping was performed with both isotope and blue dye. All SLNs were submitted for pathologic evaluation with hematoxylin and eosin stains as well as immunohistochemical stains. Some patients underwent prophylactic mastectomy with immediate reconstruction.

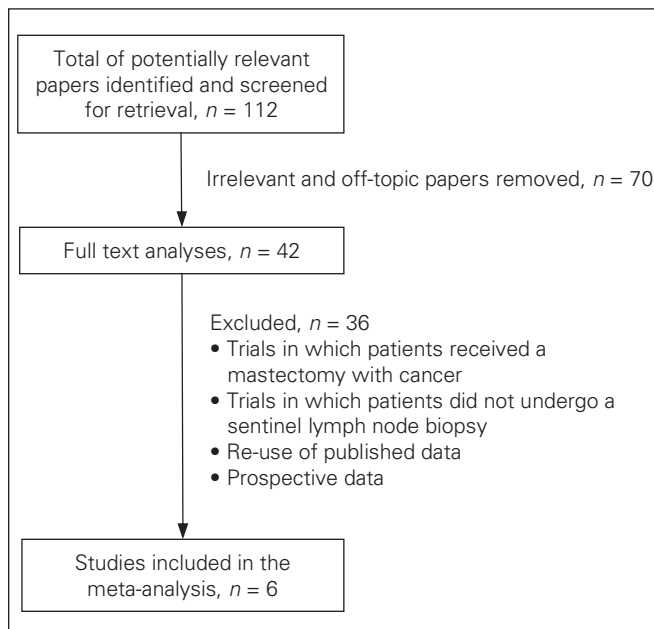


Fig. 1. Selection of studies for the meta-analysis of sentinel lymph node biopsy at the time of prophylactic mastectomy.

Table 1. Review of studies assessing sentinel lymph node biopsy at the time of prophylactic mastectomy

Study	No. of patients	PM	Bilateral PM	Technique of SLNB	Mastectomy specimen				
					Invasive cancer	Invasive cancer with SLN+	Invasive cancer with SLN–	DCIS	SLN+ with no cancer
Schrenk et al. ¹⁹	169	169	0	Dye, dye + isotope	5	0	5	4	1
Soran et al. ²⁰	80	80	0	Dye, dye + isotope	1	0	1	3	2
Boughey et al. ²¹	108	108	0	Isotope, dye + isotope	1	0	1	NR*	2
Black et al. ²²	52	56	4	Dye, isotope, dye + isotope	1	0	1	5†	1
McLaughlin et al. ¹⁷	393	453	60	Dye + isotope	7	3	4	17	5
Laronga et al. ²³	449	477	28	Dye, dye + isotope	6	1	5	12	7
Total	1251	1343	92		21	4	17	—	18

DCIS = ductal carcinoma in situ; NR = not reported; PM = prophylactic mastectomy; SLN = sentinel lymph node; SLNB = sentinel lymph node biopsy.
 *All patients with DCIS identified at the time of prophylactic mastectomy had negative SLNs, but the number of patients was not reported.
 †The SLN was positive in 1 of 5 cases.

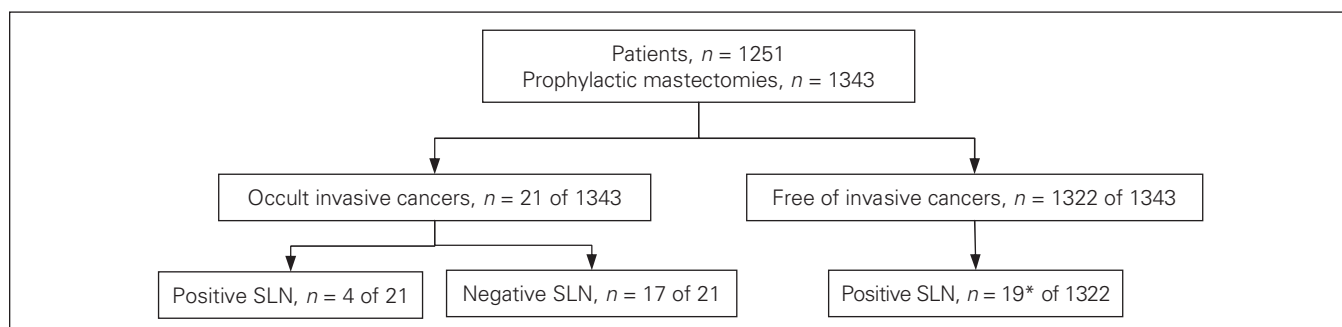


Fig. 2. Breakdown of patients undergoing prophylactic mastectomy with sentinel lymph node biopsy. *In 1 case ductal carcinoma in situ was identified in the prophylactic mastectomy specimen, and in 18 cases no cancer was identified in the specimens. SLN = sentinel lymph node.

Of these pooled 1343 prophylactic mastectomies, invasive cancers were identified in the prophylactic mastectomy specimens in 21 cases. The occult invasive cancer rate was 1.7% (95% confidence interval [CI] 1.1%–2.5%; Fig. 3). The test for heterogeneity suggested that 6 studies were not significantly heterogeneous ($\chi^2_5 = 2.37$, $p = 0.80$). In these 21 cases, most patients had invasive ductal carcinomas, and most cancers were in stage T1a. In 4 cases the SLNs were positive and in 17 cases they were negative. The patients with negative SLNs could avoid ALND.

Ductal carcinomas in situ (DCIS) were identified in 41 of 1235 prophylactic mastectomy specimens from 5 studies. Of these 41 cases, there was only 1 positive SLN. This result (< 5%) was concordant with that reported in a meta-analysis of SLNB in patients with DCIS.²⁴

Also, there were 18 cases of positive SLNs at the time of prophylactic mastectomy where no occult cancer was identified in mastectomy specimens. In total, there were 23 cases of positive SLNs, and the positive SLN rate was 1.9% (95% CI 1.2%–2.6%; Fig. 4). There was no significant between-study heterogeneity among the 6 studies ($\chi^2_5 = 3.14$, $p = 0.68$). In 19 cases, patients with positive SLNs at the time of prophylactic mastectomy were found not to have invasive cancer and needed ALND. In 17 cases, patients with negative SLNs at the time of prophylactic mastectomy were found to have invasive cancer and avoided ALND. Overall, in 36 cases, patients were considered to have benefitted from SLNB, and the benefit rate was 2.8% (95% CI 2.0%–3.8%; Fig. 5). No significant between-study heterogeneity ($\chi^2_5 = 3.69$,

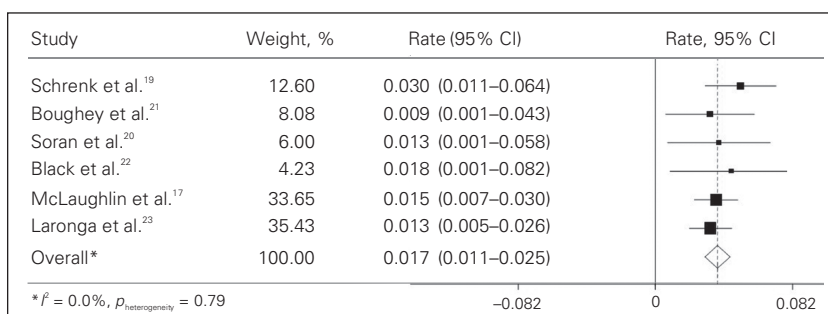


Fig. 3. Invasive cancer rate in patients who had prophylactic mastectomies. The width of the horizontal line represents the 95% confidence interval (CI) of the individual studies, and the square proportionally represents the weight of each study. The diamond represents the pooled invasive cancer rate and 95% CI.

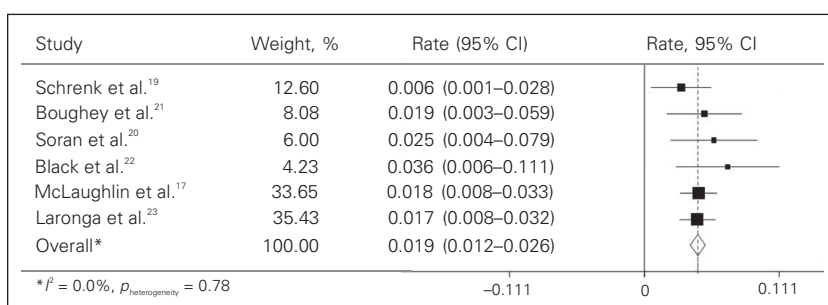


Fig. 4. Rate of positive sentinel lymph nodes. The width of the horizontal line represents the 95% confidence interval (CI) of the individual studies, and the square proportionally represents the weight of each study. The diamond represents the pooled positive sentinel lymph node rate and 95% CI.

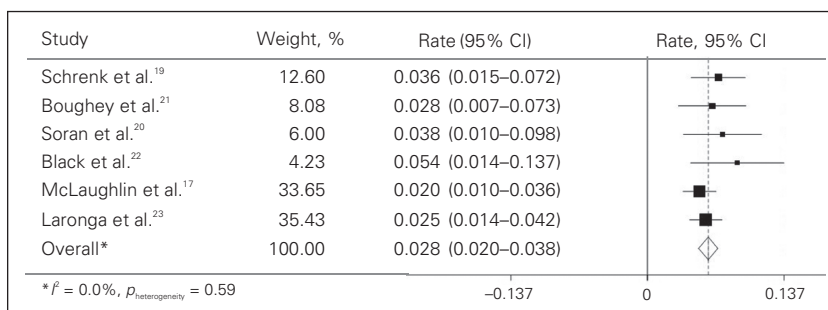


Fig. 5. Rate of the benefit of sentinel lymph node biopsy in patients who had prophylactic mastectomies. The width of the horizontal line represents the 95% confidence interval (CI) of the individual studies, and the square proportionally represents the weight of each study. The diamond represents the pooled benefit rate and 95% CI.

$p = 0.59$) was observed. Publication bias was not observed in this review ($p = 0.36$ for the occult invasive cancer rate and $p = 0.32$ for the positive SLN rate).

Features of patients with positive SLNs

Some studies analyzed the clinical features of the patients who had positive SLNs. Of the 23 cases of positive SLNs, 12 patients had advanced disease on the contralateral breast (Table 2). In the study by Laronga and colleagues,²³ 57 patients had newly diagnosed locally advanced breast cancer and chose to have a contralateral prophylactic mastectomy. Of these, 8 patients (14%) had contralateral positive SLNs. However, McLaughlin and colleagues¹⁷ reported different results: 5 patients had positive SLNs with no occult cancer identified in prophylactic mastectomy specimens, and all 5 had a concurrent contralateral cancer ranging in size from 0.1 cm to 3.0 cm. Patients with locally advanced primary breast cancer seem to be at increased risk of positive SLNs in the contralateral breast.

DISCUSSION

We conducted this systematic review to give an overview of the literature on the benefit of SLNB at the time of prophylactic mastectomy. Of the pooled patient population, 1.7% had occult invasive cancer identified in prophylactic mastectomy specimens, and 1.9% had positive SLNs. We found that in 36 cases, patients (2.8%) were considered to have benefitted from SLNB at the time of prophylactic mastectomy. The positive SLN rate was high in patients with a locally advanced cancer in the contralateral breast.

Sentinel lymph node biopsy has been shown to be feasible and safe for staging the axilla in patients with breast cancer,²⁵⁻²⁷ which provides more accurate lymph node staging and avoids the morbidity associated with a complete ALND, which has a high rate of complications, including lymphedema, pain, numbness and limited shoulder movement. Moreover, most patients have negative SLNs at the time of prophylactic mastectomy, and performing ALND in these patients would expose them to the associated com-

plications with no apparent benefit. However, SLNB at the time of prophylactic mastectomy remains controversial. Of the 1343 pooled prophylactic mastectomies performed, in only 17 cases were patients able to avoid ALND. The benefit from avoiding unnecessary ALND was not enough to support the routine use of SLNB.

Arguments against performing SLNB at the time of prophylactic mastectomy refer to the risks associated with the SLNB procedure. Sentinel lymph node biopsy has less associated morbidity than ALND; however, recent clinical trials have concluded that the complication rates of SLNB are higher than before. The ALMANAC trial²⁸ reported that the rates of lymphedema and sensory loss for patients who received SLNBs were 5% and 11%, respectively, at 12 months. In the trial by Wilke and colleagues,²⁹ 8.6% of patients had axillary paresthesias, 3.8% had a decreased upper extremity range of motion and 6.9% demonstrated proximal upper extremity lymphedema at 6 months. Other complications related to SLNB at the time of prophylactic mastectomy, such as axillary seroma,²⁰ blue hives and axillary hematomas,¹⁹ have been reported. Considering that most patients will be exposed to the risk of complications of SLNB and few patients will benefit from the procedure being performed at the time of prophylactic mastectomy, we conclude that performing SLNB at this time may not be suitable for all patients.

Sentinel lymph node biopsy can identify positive SLNs in patients in whom no occult cancer is identified in prophylactic mastectomy specimens. Axillary lymph node metastases may be the first manifestation of occult ipsilateral breast cancer, even when no tumour is found histologically.³⁰ Axillary metastases from a contralateral breast cancer are uncommon, with only a few reports described in the literature.³¹ If there is no contralateral breast cancer, the axillary metastases should be recognized as the manifestation of occult ipsilateral breast cancer. The patients with diagnosed occult breast cancer should be treated according to standard guidelines. If there is contralateral breast cancer, the axillary metastases could be recognized as the manifestation of occult ipsilateral breast cancer or as the metastases from the contralateral cancer. If axillary metastases from a contralateral breast cancer are confirmed, they should be classified as distant metastases and the contralateral breast cancer should be designated stage IV. Of all the pooled patients who had prophylactic mastectomies, there was 1 case of a positive SLN with DCIS identified in the mastectomy specimen and 18 cases of positive SLNs without primary cancer identified in the ipsilateral breast mastectomy specimens. In these 19 cases, patients who required a second surgery were considered to have benefitted from SLNB. We believe that these patients represent crossover metastases to the opposite axilla. Because about half of the patients with axillary metastases are reported to have had locally advanced disease on the contralateral breast, locally advanced breast cancer may play an

Table 2. Features of patients with positive sentinel lymph nodes (SLNs)

Study	No. positive SLNs	Features of contralateral breast
Schrenk et al. ¹⁹	1	—
Soran et al. ²⁰	2	1 locally advanced breast cancer, 1 recurrent disease
Boughey et al. ²¹	2	1 locally advanced breast cancer
Black et al. ²²	2	1 locally advanced breast cancer
McLaughlin et al. ¹⁷	8	—
Laronga et al. ²³	8	8 locally advanced breast cancer
Total	23	11 locally advanced breast cancer, 1 recurrent disease

important role in contralateral nodal involvement.³² However, further research involving patients with advanced disease on the contralateral breast is necessary.

Our review suggests that a positive SLN of the mastectomized breast may be related to advanced cancer on the contralateral breast. However, the risk factors associated with contralateral axilla were not evaluated in previous studies. In the study by Yi and colleagues,³³ an increased Gail risk (5-yr risk $\geq 1.67\%$), an additional ipsilateral moderate- to high-risk pathology, an ipsilateral multicentric tumour or an ipsilateral tumour of invasive lobular histology increased the risk of contralateral breast cancer, but no correlation between those risk factors and positive SLNs of the mastectomized breast was observed. To evaluate the risk factors associated with contralateral axillary metastases, further clinical trials should be conducted.

In this review, we found that in 36 cases (2.8%), patients were considered to have benefitted from SLNB and that SLNB may not be suitable for all patients undergoing prophylactic mastectomy. However, in the only prospective study we found in our search,¹⁸ the benefit rate was greater (7%). In this study, 2 patients with negative SLNs in whom invasive cancer was identified in prophylactic mastectomy specimens were able to avoid ALND. Another 2 patients with positive SLNs in whom no invasive cancer was identified in mastectomy specimens needed a subsequent ALND. Four patients (7%) were considered to have benefitted from SLNB at the time of prophylactic mastectomy. The studies included in this meta-analysis were all retrospective, and not all patients who received prophylactic mastectomies underwent an SLNB in the primary studies. Indications for prophylactic mastectomy were different in the included studies and that may have influenced the positive SLN rate. Larger prospective trials, especially in light of the increasing rates of prophylactic mastectomies performed, may further elucidate this topic.

CONCLUSION

The benefit rate of SLNB at the time of prophylactic mastectomy was 2.8% in our review; this rate is too low to support the routine use of SLNB at the time of prophylactic mastectomy. However, SLNB at this time may be suitable for a subgroup of patients with locally advanced breast cancers who may have increased risk of occult cancer in the contralateral axilla. More studies should be performed to determine what risk factors should be present for patients to undergo SLNB at the time of prophylactic mastectomy in the future.

Acknowledgement: We thank Professor Jifu Wei for his help in revising the manuscript.

Competing interests: None declared.

Contributors: Drs. Zhou, Liu and Wang designed the study. Drs. Zhou and Liu acquired the data, which Drs. Dai and Wang analyzed.

Drs. Zhou and Liu wrote the article, which all authors reviewed and approved for publication.

References

- Hartmann LC, Schaid DJ, Woods JE, et al. Efficacy of bilateral prophylactic mastectomy in women with a family history of breast cancer. *N Engl J Med* 1999;340:77-84.
- Eldor L, Spiegel A. Breast reconstruction after bilateral prophylactic mastectomy in women at high risk for breast cancer. *Breast J* 2009;15: S81-9.
- Rebeck TR, Friebel T, Lynch HT, et al. Bilateral prophylactic mastectomy reduces breast cancer risk in BRCA1 and BRCA2 mutation carriers: the PROSE Study Group. *J Clin Oncol* 2004;22:1055-62.
- Tuttle T, Habermann E, Abraham A, et al. Contralateral prophylactic mastectomy for patients with unilateral breast cancer. *Expert Rev Anticancer Ther* 2007;7:1117-22.
- Schrag D, Kuntz KM, Garber JE, et al. Life expectancy gains from cancer prevention strategies for women with breast cancer and BRCA1 or BRCA2 mutations. *JAMA* 2000;283:617-24.
- McDonnell SK, Schaid DJ, Myers JL, et al. Efficacy of contralateral prophylactic mastectomy in women with a personal and family history of breast cancer. *J Clin Oncol* 2001;19:3938-43.
- Tuttle TM, Habermann EB, Grund EH, et al. Increasing use of contralateral prophylactic mastectomy for breast cancer patients: a trend toward more aggressive surgical treatment. *J Clin Oncol* 2007;25:5203-9.
- Herrinton LJ, Barlow WE, Yu O, et al. Efficacy of prophylactic mastectomy in women with unilateral breast cancer: a cancer research network project. *J Clin Oncol* 2005;23:4275-86.
- Giuliano AE, Jones RC, Brennan M, et al. Sentinel lymphadenectomy in breast cancer. *J Clin Oncol* 1997;15:2345-50.
- Lyman GH, Giuliano AE, Somerfield MR, et al. American Society of Clinical Oncology guideline recommendations for sentinel lymph node biopsy in early-stage breast cancer. *J Clin Oncol* 2005;23:7703-20.
- Cody HS III. Clinical aspects of sentinel node biopsy. *Breast Cancer Res* 2001;3:104-8.
- van Deurzen CH, Vriens BE, Tjan-Heijnen VC, et al. Accuracy of sentinel node biopsy after neoadjuvant chemotherapy in breast cancer patients: a systematic review. *Eur J Cancer* 2009;45:3124-30.
- Lau J, Ioannidis JP, Schmid CH. Quantitative synthesis in systematic reviews. *Ann Intern Med* 1997;127:820-6.
- Petitti DB. *Meta-analysis, decision analysis, and cost-effectiveness analysis*. New York (NY): Oxford University Press; 1994.
- Egger M, Davey Smith G, Schneider M, et al. Bias in meta-analysis detected by a simple, graphical test. *BMJ* 1997;315:629-34.
- King TA, Ganaraj A, Fey JV, et al. Cytokeratin-positive cells in sentinel lymph nodes in breast cancer are not random events. *Cancer* 2004;101:926-33.
- McLaughlin SA, Stempel M, Morris EA, et al. Can magnetic

- resonance imaging be used to select patients for sentinel lymph node biopsy in prophylactic mastectomy? *Cancer* 2008;112:1214-21.
18. Dupont EL, Kuhn MA, McCann C, et al. The role of sentinel lymph node biopsy in women undergoing prophylactic mastectomy. *Am J Surg* 2000;180:274-7.
 19. Schrenk P, Wöfl S, Bogner S, et al. Symmetrization reduction mammoplasty combined with sentinel node biopsy in patients operated for contralateral breast cancer. *J Surg Oncol* 2006;94:9-15.
 20. Soran A, Falk J, Bonaventura M, et al. Is routine sentinel lymph node biopsy indicated in women undergoing contralateral prophylactic mastectomy? Magee-Women's Hospital experience. *Ann Surg Oncol* 2007;14:646-51.
 21. Boughey JC, Khakpour N, Meric-Bernstam F, et al. Selective use of sentinel lymph node surgery during prophylactic mastectomy. *Cancer* 2006;107:1440-7.
 22. Black D, Specht M, Lee JM, et al. Detecting occult malignancy in prophylactic mastectomy: preoperative MRI versus sentinel lymph node biopsy. *Ann Surg Oncol* 2007;14:2477-84.
 23. Laronga C, Lee MC, McGuire KP, et al. Indications for sentinel lymph node biopsy in the setting of prophylactic mastectomy. *J Am Coll Surg* 2009;209:746-52.
 24. Ansari B, Ogston SA, Purdie CA, et al. Meta-analysis of sentinel node biopsy in ductal carcinoma in situ of the breast. *Br J Surg* 2008;95:547-54.
 25. Giuliano AE, Dale PS, Turner RR, et al. Improved axillary staging of breast cancer with sentinel lymphadenectomy. *Ann Surg* 1995;222:394-9.
 26. Cox CE, Pendas S, Cox JM, et al. Guidelines for sentinel node biopsy and lymphatic mapping of patients with breast cancer. *Ann Surg* 1998;227:645-51.
 27. Veronesi U, Paganelli G, Viale G, et al. A randomized comparison of sentinel-node biopsy with routine axillary dissection in breast cancer. *N Engl J Med* 2003;349:546-53.
 28. Mansel RE, Fallowfield L, Kissin M, et al. Randomized multicenter trial of sentinel node biopsy versus standard axillary treatment in operable breast cancer: the ALMANAC trial. *J Natl Cancer Inst* 2006;98:599-609.
 29. Wilke LG, McCall LM, Posther KE, et al. Surgical complications associated with sentinel lymph node biopsy: results from a prospective international cooperative group trial. *Ann Surg Oncol* 2006;13:491-500.
 30. Patel J, Nemoto T, Rosner D, et al. Axillary lymph node metastasis from an occult breast cancer. *Cancer* 1981;47:2923-7.
 31. Daoud J, Meziou M, Khararrat M, et al. Contralateral axillary lymph node metastasis of cancer of the breast. *Bull Cancer* 1998;85:713-5.
 32. Agarwal A, Heron DE, Sumkin J, et al. Contralateral uptake and metastases in sentinel lymph node mapping for recurrent breast cancer. *J Surg Oncol* 2005;92:4-8.
 33. Yi M, Meric-Bernstam F, Middleton LP, et al. Predictors of contralateral breast cancer in patients with unilateral breast cancer undergoing contralateral prophylactic mastectomy. *Cancer* 2009;115:962-71.

CJS's top articles, September 2011*

1. **Research questions, hypotheses and objectives**
Farrugia et al.
Can J Surg 2010;53(4):278-81
2. **Tracheostomy: from insertion to decannulation**
Engels et al.
Can J Surg 2009;52(5):427-33
3. **Chest tube complications: How well are we training our residents?**
Ball et al.
Can J Surg 2007;50(6):450-8
4. **Endoscopic plantar fasciotomy in the treatment of chronic heel pain**
Urovitz et al.
Can J Surg 2008;51(4):281-3
5. **Treatment of an infected total hip replacement with the PROSTALAC system**
Scharfenberger et al.
Can J Surg 2007;50(1):24-8
6. **The efficacy and risks of using povidone-iodine irrigation to prevent surgical site infection: an evidence-based review**
Chundamala and Wright
Can J Surg 2007;50(6):473-81
7. **Incidence of intramedullary nail removal after femoral shaft fracture healing**
Hui et al.
Can J Surg 2007;50(1):13-8
8. **Patient characteristics affecting the prognosis of total hip and knee joint arthroplasty: a systematic review**
Santaguida et al.
Can J Surg 2008;51(6):428-36
9. **Combined large Hill-Sachs and bony Bankart lesions treated by Latarjet and partial humeral head resurfacing: a report of 2 cases**
Grondin and Leith
Can J Surg 2009;52(3):249-54
10. **Current thinking about acute compartment syndrome of the lower extremity**
Shadgan et al.
Can J Surg 2010;53(5):329-34

* Based on page views on PubMed Central of research, reviews, commentaries and continuing medical education articles.