

# Atypical presentation of spinal tuberculosis

Aparna Sarangapani, BHSc;\* Aria Fallah, BSc;† John Provias, MD;‡ Neillank K. Jha, MD§

**P**ulmonary tuberculosis is a chronic infectious disease caused by *Mycobacterium tuberculosis* and characterized by the presence of granuloma.<sup>1</sup> Features of spinal tuberculosis (Pott disease), an extrapulmonary form, include destruction of the intervertebral space and collapse of vertebral bodies, leading to progressive kyphosis.<sup>2</sup> The thoracic spine is the most common site of tuberculous infection.<sup>3</sup> We present a case of spinal tuberculosis in a 26-year-old man with an initial misdiagnosis of a metastatic bone tumour of unknown origin.

## Case report

A 26-year-old man presented with a 4-month history of pain in the right shoulder and ribs. He reported non-specific numbness in the thoracic and abdominal region and in his lower extremities bilaterally. Physical examination was remarkable only for bilateral leg numbness and weakness that was worse on the right side. Computed tomography (CT) and magnetic resonance imaging of the chest and thoracic spine showed lytic bone lesions, secondary pathologic fractures and nerve-root compression; all characteristics were consistent with a neoplasm (Fig. 1).

Because we were concerned that the lesions were malignant, we planned a T2–T4 decompressive laminectomy and T1–T6 pedicle screw instrumentation and fusion. Intraoperatively, the lesion appeared pus-like. The spinal cord was decompressed.

Pathological examination of the excised specimen indicated the presence of a tuberculous granuloma and not a malignant tumour.

The final diagnosis was an atypical presentation of spinal tuberculosis. He received appropriate antituberculous therapy and recovered well.

## Discussion

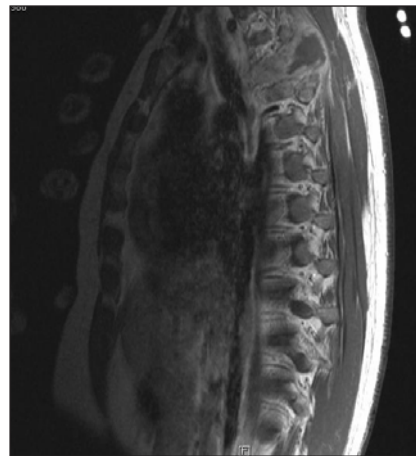
Recognition and a thorough understanding of radiologic images may aid in the diagnosis of spinal tuberculosis.<sup>4</sup> Although our patient exhibited many characteristics of spinal tuberculosis, its diagnosis was

challenging. Tuberculous infections can mimic other bacterial, fungal, inflammatory and neoplastic diseases. Furthermore, owing to its low prevalence in western countries compared with developing countries, many physicians in the West are unfamiliar with the presentation and not sufficiently aware of this disease. However, with the increasing diversity of Canada's multicultural society and the frequency of international travel, it is prudent to consider disease entities that have a low prevalence locally. In our patient, the misdiagnosis led to delayed antimicrobial therapy and resulted in surgical intervention. Retrospectively, the diagnosis could have been confirmed more appropriately by a CT-guided biopsy.

**Competing interests:** None declared.

## References

1. Ernst JD, Trevejo-Nuñez G, Banaiee N. Genomics and the evolution, pathogenesis, and diagnosis of tuberculosis. *J Clin Invest* 2007;117:1738-45.
2. Joseffer SS, Cooper PR. Modern imaging of spinal tuberculosis. *J Neurosurg Spine* 2005;2:145-50.
3. Tanriverdi T, Kizilkiliç O, Hanci M, et al. Atypical intradural spinal tuberculosis: report of three cases. *Spinal Cord* 2003;41:403-9.
4. Ahmadi J, Bajaj A, Destian S, et al. Spinal tuberculosis: atypical observations at MR imaging. *Radiology* 1993;189:489-93.



**FIG. 1.** Sagittal T<sub>1</sub>-weighted postgadolinium magnetic resonance imaging of the thoracolumbar spine shows heterogeneous, mostly hyperintense lesions involving the T3 and T4 vertebrae.

From the \*Bachelor of Health Sciences Program, the †Michael G. DeGroot School of Medicine, the ‡Department of Pathology and the §Division of Neurosurgery, Department of Surgery, McMaster University, Hamilton, Ont.

Accepted for publication Jan. 22, 2008

**Correspondence to:** Dr. N.K. Jha, c/o Bruna Capretta, Department of Pathology and Molecular Medicine, Hamilton Health Sciences — General Site, 237 Barton St. E, Hamilton ON L8L 2X2; fax 905 524-2681; caprebru@hhsc.ca